

## Management of sternotomy dehiscence



**Author:**  
Fozia Choukairi

Sternal wound complications may result from median sternotomy procedures following cardiothoracic surgery and can represent a significant management problem in open cardiac surgery leading to increased morbidity and mortality. Morbidity from sternal wound dehiscence was close to 50% until recently, but with new advances, including sternal fixation techniques and various reconstructive surgical options, and up-to-date protocols for surgical site infections (PHE, 2019), this has improved significantly. This article outlines the problems of wound dehiscence and delayed healing following median sternotomy and provides an overview of the pertinent management options.

**S**ternal wound complications may result from median sternotomy procedures following cardiothoracic surgery. The median sternotomy is the incision of choice for most procedures that involve the heart and great vessels, including trauma, bypass, valve replacement, heart failure and transplant surgery. In addition, it allows access for many pulmonary procedures (Falor and Traylor, 1982). When compared to approaching the chest cavity from the lateral side (lateral thoracotomy), the median sternotomy provides excellent exposure and results in less postoperative pain (Falor and Traylor, 1982).

However, postoperative wound infection of the sternum is common and if severe, chronic or untreated, can lead to sternal wound dehiscence. The incidence of sternal wound infections following median sternotomy procedures is in the region of 0.5–8.4% (Grevious et al, 2018; Listewnik, 2019). This can be further complicated by the development of osteomyelitis of the sternum which has a reported incidence of 3% (Berdajs, 2011).

Sternal wound dehiscence may lead to mediastinitis, which is where the superficial wound infection can potentially extend deeper and affect the mediastinal structures (Lazar, 2016). It has an incidence of 1–5% of median sternotomies (Lazar, 2016; Grevious et al, 2018).

Morbidity from sternal wound dehiscence and its associated complications was reported to be approximately 50% until recently (Shumacker and Mandelbaum, 1963; Losanoff et al, 2002), but advances in management options and medical devices, such as negative pressure wound therapy (NPWT), has reduced the morbidity rate to

approximately 10% (Miller and Nahai, 1989; Jones et al, 1997; Sjögren et al, 2006).

Sternal wound infections and dehiscence also prolong recovery time as well as increasing hospital stay, re-operative rates, morbidity and mortality (Losanoff et al, 2002; Fu et al, 2016). This article aims to highlight the problems of sternal wound dehiscence and delayed healing following median sternotomy, as well as providing an overview of the management options.

### Medial Sternotomy

Median sternotomy was re-introduced in the 1950s by Julian et al (1957) and has revolutionised the world of cardiothoracic surgery. The midline incision is made through the bony sternum and provides excellent exposure of vital chest structures permitting a wide range of intra-thoracic procedures (Grevious et al, 2018).

Other incisions exist and newer minimally invasive approaches are being developed, however, the median sternotomy remains the incision of choice for many procedures since it provides the best access to the mediastinal structures as well as access into both hemithoraces. It is considered to be less painful and provides a lower incidence of respiratory complications when compared to other incisions (Farhat et al, 2004).

### Delayed wound healing

Following a median sternotomy, the integrity of the sternum and the surrounding structures are significantly compromised. Consequently, the reduced post-operative blood supply combined with high stresses and almost constant movement, which are both due to respiration

## Box 1. Risk factors for sternal wound complications (Abu-Omar et al, 2017)

### Patient risk factor

- Increasing age
- Female sex
- Diabetes mellitus
- Obesity
- Smoking
- Malnutrition
- Sepsis
- Renal failure
- Immunosuppression
- Osteoporosis
- Chronic obstructive pulmonary disease (COPD)

### Surgical factors

- Poor technique
- Extended operative time
- Prolonged ventilation
- Insufficient sternal fixation
- Excessive haemorrhage
- Bilateral internal mammary artery harvest
- Cardiopulmonary bypass
- Hypoperfusion
- Use of bone wax

and activities of the shoulder girdle, predispose to instability and possible osteomyelitis (Lazar, 2016).

Sternal wound complications are multifactorial including patient-related factors, intra-operative and post-operative variables including length of hospital stay. The spectrum of sternotomy wound complications extend between superficial and deep wound infection, wound dehiscence, osteomyelitis and mediastinitis (Abu-Omar et al, 2017) [Box 1].

### Deep sternal infection and sequelae

A common mechanism by which sternal complications occur is the loss of stability of the sternotomy closure site. Cerclage stainless steel wires remain the current standard technique for sternal closure and can fail under normal physiological loads. Mechanical stress at the steel wires can lead to these wires becoming imbedded within the sternal bones thereby allowing excessive mobility at the closure site.

Long-term problems include sternal instability, paradoxical motion of the chest wall and chronic pain. These symptoms may have significant effects on the patient's quality of life.

Pairolero and Arnold (1984) classified sternal wound infections into three types based on timing and presentation [Table 1]. This system does not necessarily indicate the type of treatment required, however, type II and III will generally require surgical debridement of infected tissue and bone with removal of sternal metalwork and subsequent surgical reconstruction (Pairolero and Arnold, 1984).

Rupprecht et al (2013) further classified sternal complications into superficial/deep sternal wound infections with or without sternal instability. Sternal instability without infection is attributed to high tensile forces after surgery and leads to loss of sternal wall stability. Deep sternal wall infection without sternal instability occurs in patients with impaired wound healing in an area of excessive soft tissue tension and

tight closure. Deep sternal wound infection with sternal instability is associated with the highest morbidity and mortality. Excessive movement of the sternal edges due to sternal metalwork loosening or failure leads to chronic inflammation and deep infection with subsequent loss of sternal wall integrity and bone loss. These patients can develop respiratory problems often associated with pneumonia (Rupprecht et al, 2013).

In the UK, Public Health England (PHE) has developed a protocol for surveillance of surgical site infections (SSIs) (PHE, 2019). This protocol defines SSIs according to standard clinical criteria for infections that affect the superficial tissues (skin and subcutaneous layer) of the incision and those that affect the deeper tissues (deep incisional or organ/space). These are based on the definitions established by the US Centers for Disease Control and Prevention (CDC) (Horan et al, 1992).

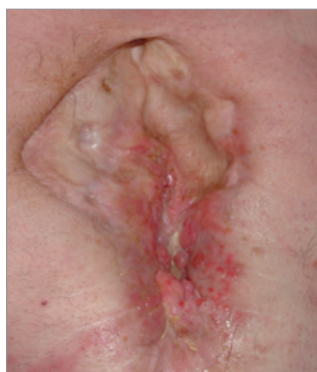### Initial assessment for sternotomy dehiscence

An accurate clinical evaluation is essential to recognize the early signs and symptoms of sternal wound dehiscence. Clinicians should be alert for signs of local wound changes such as erythema or increased exudate, pain, systemic signs such as pyrexia, and respiratory symptoms (e.g. pleural effusions). Clinicians should be extra-alert to the possibility of complications in high-risk patients, such as increased risk of infection, delayed wound healing and wound dehiscence (Losanoff et al, 2002a). Chronic wounds can point to underlying osteomyelitis and underlying sternal instability [Figures 1, 2, 3].

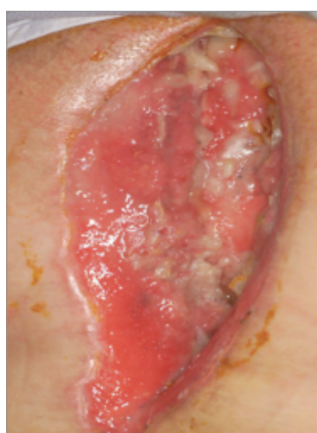If infection is suspected or is localised and minimal clinically, it is reasonable to withhold antibiotics until microbiological swab results (provisional or definitive) are available, or at least after obtaining tissue samples (either on the ward or in the theatre) for microbiological analysis (Grevious et al, 2018). If empirical broad-spectrum

**Table 1. Pairolero and Arnold Classification System of Mediastinitis (Pairolero and Arnold, 1984)**

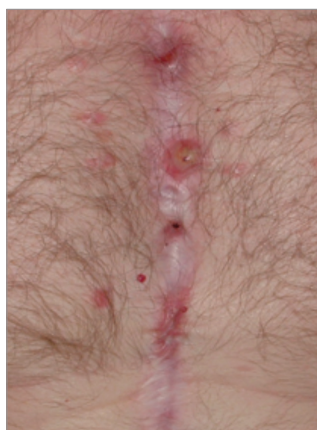<b>Type 1</b>	<ul style="list-style-type: none"> <li>■ Occurs within a few days of initial surgery</li> <li>■ There is serosanguinous discharge but no evidence of cellulitis, osteomyelitis or costochondritis</li> <li>■ There are no signs of wound breakdown or instability</li> </ul>
<b>Type 2</b>	<ul style="list-style-type: none"> <li>■ Occurs in the first few weeks following surgery</li> <li>■ Characterised by drainage, cellulitis and positive cultures</li> <li>■ Usually classed as fulminant mediastinitis, often with bony involvement</li> </ul>
<b>Type 3</b>	<ul style="list-style-type: none"> <li>■ Chronic wounds occurring months or years after surgery</li> <li>■ Incorporate signs of chronic infection with sinuses, cellulitis and osteomyelitis</li> <li>■ Medistinal involvement is uncommon with type III infections</li> </ul>



**Figure 1.** Chronic sternal wound



**Figure 2.** A chronic non-healing dehiscenced sternal wound



**Figure 3.** Sternal osteomyelitis. This patient presented with chronic non-healing sinuses initially thought to be the result of sternal wire reaction. However, at time of surgery to remove the wires bony changes were identified and osteomyelitis was confirmed on bone biopsy

antibiotics may be started if the infection is overwhelming with surrounding progressive cellulitis, mediastinitis, systemic infection or sepsis (Grevious et al, 2018).

Several studies have reported on the spectrum of pathogens in sternal wound infection following cardiac surgery. Chaudhuri et al (2011) demonstrated that *Staphylococcus aureus* is the most common organism cultured from deep sternal tissue, with half of cultured organisms being methicillin-sensitive, followed by coagulase-negative *Staphylococcus aureus*. Gram-negative organisms such as *Pseudomonas aeruginosa* were less commonly found in cultured tissues.

More recently, Kotnis-Gaska et al (2018), in a study that evaluated 2,869 cardiac surgeries and identified 114 patients with sternal wound infections during a 16-month period, showed that the main causative pathogen of infection in sternal wound infection was the commensal *Staphylococcus epidermidis*. Micro-organisms that colonize these wounds tend to form biofilms, which are polymicrobial communities that line tissues and protects them from host immune systems and render them resistant to antibiotic treatment. Forty-eight patients (42.1%) in their study had polymicrobial infections. Furthermore, their study demonstrated the mortality rates in patients with or without infection were 14.6% and 3 % respectively.

The key aim, once infection is identified, is prompt treatment with superficial infections being treated with guided antibiotic therapy. For deep infections with or without sternal instability, surgical debridement should be undertaken, following which further management can be decided upon. The aim of surgical debridement is to remove all non-viable tissue back to bleeding tissue and produce a clean wound that allows definitive management to be instituted immediately or at a delayed stage (Grevious et al, 2018). If there is evidence of mediastinitis and extensive disruption of the sternum, more radical surgery and reconstruction should be considered (Grevious et al, 2018).

If surgical treatment is planned, pre-operative baseline investigations (e.g. full blood count, serum electrolytes, inflammatory markers such as C-reactive protein and serum albumin levels) are needed to ensure the patient's fitness for general anaesthesia.

Imaging studies can be obtained in equivocal cases. Plain radiography of the sternum may demonstrate mediastinal air or separation of the sternal half (when performing a median

sternotomy, the sternal bone is longitudinally [vertically] sawn in half and the 'sternal half' refers to these two halves of bone) (Gualdi et al, 2005). Ultrasound may be used to identify any collections of fluid. Computerised tomography (CT) scans are useful for detecting sternal disruption, the location of fluid, and any underlying lung or mediastinal pathology. If osteomyelitis is suspected a magnetic resonance imaging (MRI) scan can be used. However, the effectiveness of any MRI may be limited by the presence of sternal metalwork (Gualdi et al, 2005). Intra-operative superficial wound swabs, deep-tissue biopsies and bone biopsies should be obtained for microbiological analysis and assist the accurate diagnosis of osteomyelitis in a clinical setting (O'Brien Norris, 1995).

### Management of sternotomy dehiscence

A number of factors need to be considered when evaluating and managing non-healing sternal wounds [Figure 2], including:

- Presence and depth of infection
- Any evidence of underlying osteomyelitis [Figure 3]
- Anatomy of any tissue defects
- Sternal stability
- General health of the patient and any associated comorbidities.

In the 1950s, dehiscenced and non-healing sternal wounds were mostly left to heal by secondary intention, which included debridement, packing and open drainage. However, with these techniques alone, morbidity was close to 50%. In 1963, the concept of catheter antibiotic irrigation of sternal wounds was introduced, leading to a reduction in morbidity from 50% to approximately 20% (Shumacker and Mandelbaum, 1963). Although this reduction was considered to be a significant step forward, it was associated with a major complication — the erosion of major vessels by the catheter, leading in some cases to fatal haemorrhage (Grevious et al, 2018). This resulted in the drive for better and alternative management options.

Current treatment options include:

Promoting healing by secondary intention through the use of NPWT

- Split-skin grafting if appropriate
- Sternal stabilisation procedures
- Reconstructive procedures.

The above management techniques have led to a significant reduction in the incidence of morbidity and subsequent mortality from sternal wounds to approximately 10% (Miller and Nahai, 1989; Jones et al, 1997; Sjögren et

al, 2006). A suggested treatment algorithm for the management of sternal wounds is shown in **Figure 4**.

## Negative Pressure Wound Therapy

The emergence of NPWT in 1997 has greatly improved the outcomes of sternal wound dehiscence (Song et al, 2003; Agarwal et al, 2005). This therapy involves the application of a negative pressure pump to the wound via a special occlusive dressing (Sjögren et al, 2006). It can be applied to sternal wounds after initial debridement (Sjögren et al, 2006) and can either be used to encourage secondary healing in selected patients (Song et al, 2003; Malmjö et al, 2007), or as an interim measure between debridement and attempts at definitive closure (Song et al, 2003). NPWT has been shown to:

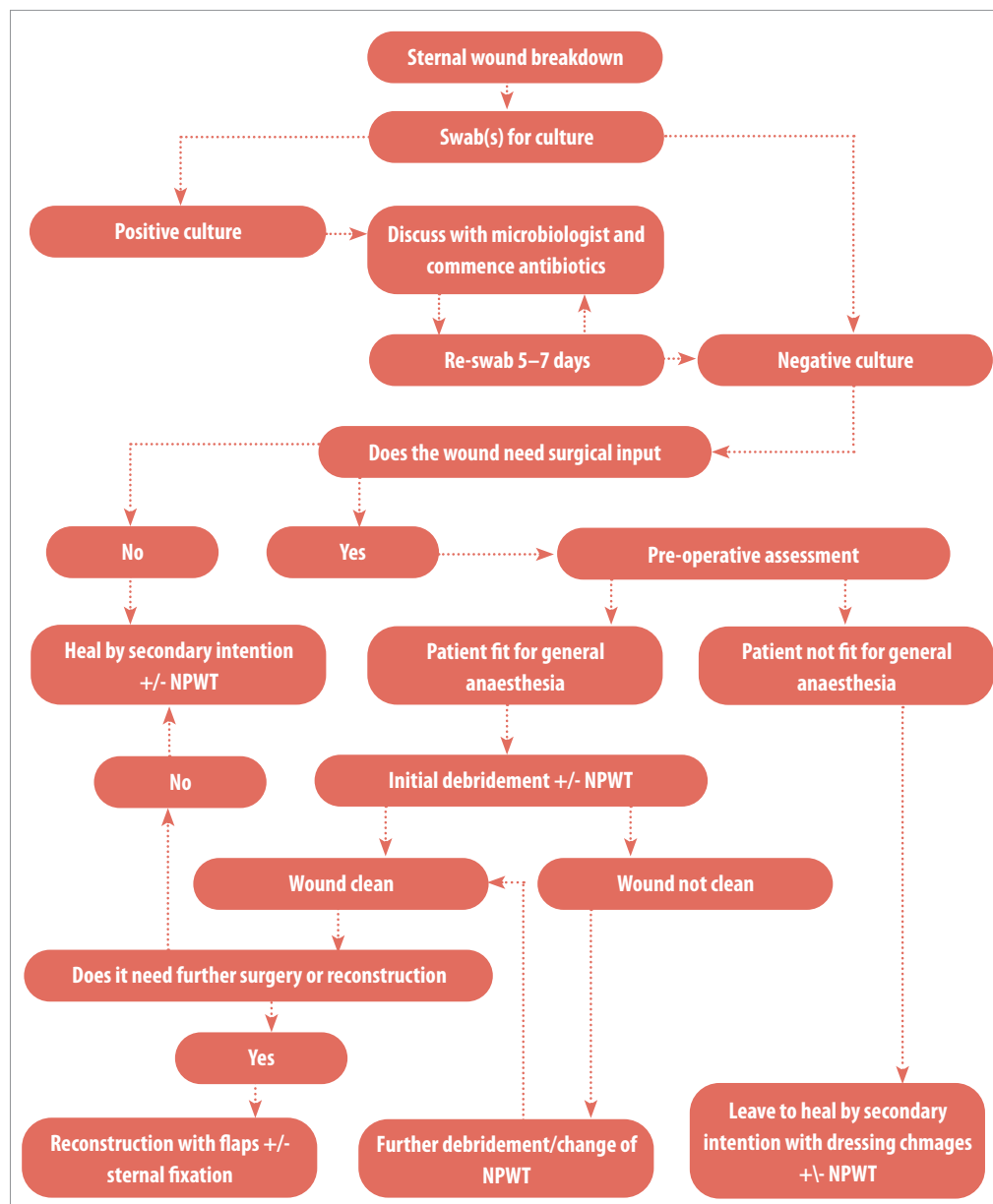
- Reduce the number of dressing changes
- Expedite time to definitive treatment
- Lower costs
- Reduce the length of in-patient stay (Agarwal et al, 2005).

NPWT has a number of local effects on sternal wound healing. It is known to decrease wound area, stimulate blood flow, remove excess fluid, and stimulate granulation tissue formation (Malmjö et al, 2007). It also helps to stabilise the sternum, thus decreasing the ventilatory requirements of intensive care patients who are receiving respiratory support.

NPWT can be used as a definitive treatment in shallow wounds in a stable non-infected sternum.

More recently, NPWT with instillation (NPWTi) has been introduced with much success in the treatment of sternal wound complications.

**Figure 4.** Algorithm summarising the management of sternal wounds



NPWTi utilises a hydrophilic foam over infected wounds and at set intervals, a solution is applied into the wound through an installation port on the foam. The solution remains in the bed for a predetermined amount of time then suction resumes to drain it. Solutions used include antiseptics such as Protonsan, hypochlorite solution (Dakin's) and antibiotic irrigation (Kim et al, 2015). Studies have shown that this is an effective method of continuously cleansing the wound thereby limiting return to theatre, shorter time to closure and fewer debridements/dressing changes (West 2018; Chowdhary and Wilhelmi, 2019). Several studies have found that NPWTi is effective at decreasing bacterial load and biofilm formation in porcine models (Singh et al, 2017; Leung et al, 2010).

A recent retrospective review of 28 patients with sternal, spinal and extremity hardware infections treated with a combination of surgical debridement and negative pressure therapy with instillation showed successful clearance of infection and healed wounds in 89% patients with 61% patients having successful salvage of original hardware (Hehr et al, 2019).

### Reconstruction with flaps

The concept of debridement and reconstruction involves the use of flaps (a unit of tissue with its own blood supply) to reduce the dead space in the sternal defect as well as to provide bulk (muscle mass or omentum) to encourage healing (José, 1999)

NPWT can be used in the interim. Previous irradiation of the chest wall or abdominal surgery may preclude the use of certain types of flaps. Therefore, a full assessment of the patient is essential before embarking on a specific type of reconstruction (O'Brien Norris, 1995; Grevious et al, 2018).

Lee et al introduced the omental flap in 1976 (Lee et al, 1976; Jurkiewicz and Arnold, 1977),

later more complex myocutaneous flaps were developed following the work of Jurkiewicz and Arnold (1977). These include the pectoralis major, rectus abdominis and latissimus dorsi flaps (Jurkiewicz et al, 1980; Tizian et al, 1985).

Defects of the upper third are most easily and successfully covered using unilateral or bilateral pectoralis muscle flaps (Jones et al, 1997). Defects of the mid and lower third and larger defects can be covered using the rectus abdominis flap (Greig et al, 2007). The two techniques can be combined for larger defects, resulting in better outcomes.

A major study by Castelló et al (1999) that examined sternal wounds demonstrated that pectoralis flaps were the most commonly used flap in sternal reconstruction, with the second choice being pectoralis combined with rectus abdominis flaps, and then the rectus abdominis muscle alone. Latissimus dorsi or omental flaps were only used in a small number of cases. The study showed that there was an overall reduction in mortality using these techniques (José et al, 1999).

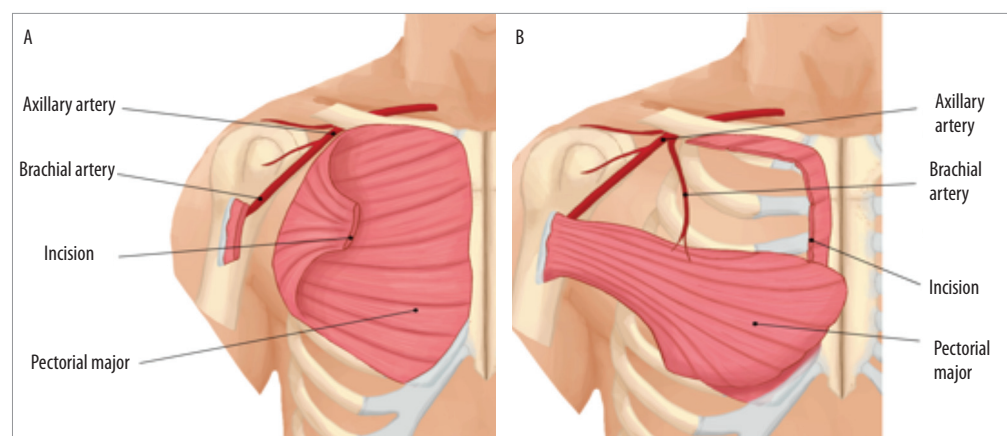
More recently, Bota et al (2019) have shown good outcomes with the use of latissimus dorsi flap for reconstruction of moderate sternal wound reconstruction with minimal donor morbidity and advocate the use of this flap as a primary option as well as salvage.

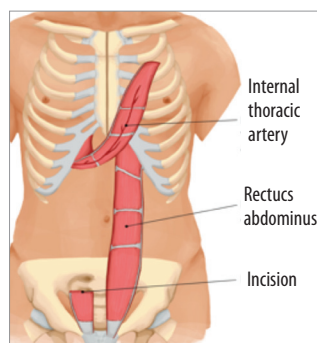
If these muscle, omental or perforator flap options are unavailable due to previous surgery, irradiation or injury or fail then microsurgical free flaps remain a good option for soft tissue coverage though this is rarely required.

### Muscle flaps

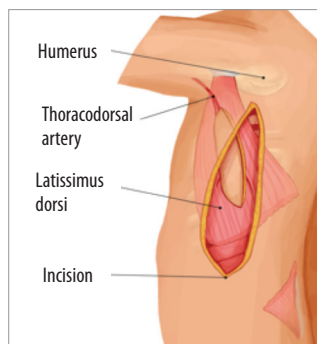
The pectoralis major flap [Figures 5a and b] is considered to be a gold standard for reconstruction of sternal defects (Greig et al, 2007). It is often the first choice due to its proximity to the defect requiring coverage. It is based on either the thoracoacromial pedicle

**Figure 5a and b.** Pectoral muscle flap: muscle turnover flap [a], muscle advancement flap [b]

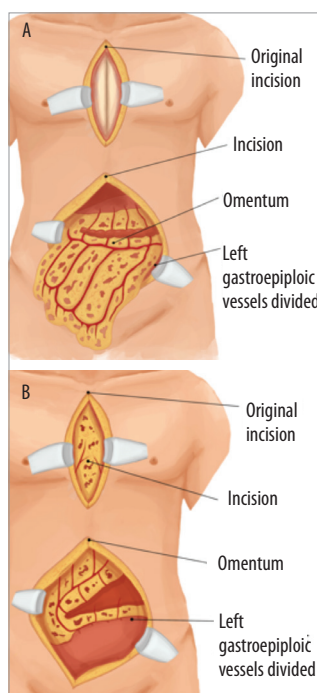




**Figure 6.** The rectus abdominus muscle divided from its insertion and raised as a flap without the overlying skin paddle. The rectus abdominus muscle from the abdomen is transposed onto the defect in the chest to cover the sternal area



**Figure 7.** Latissimus dorsi flap



**Figure 8.** Omental flap raised on left gastroepiploic artery via abdominal incision [a]. Omental flap inset over sternal wound [b]

or the internal mammary perforators and is harvested through a midline incision. It can be advanced into a defect either as a muscle or musculocutaneous flap, or as a turnover flap based on the intercostal arteries. The latter option is not always possible as the vessels are often lost during radical sternal and rib cartilage debridement. Shoulder function may be affected post-operatively, however, SahasrBudhe et al (2016) published their experience of using unilateral and bilateral pectoralis muscle flaps and reported normal shoulder function at mid to long-term follow-up.

The rectus abdominus muscle forms part of the anterior abdominal wall. It provides abdominal flexion and offers support to the abdominal contents. The rectus flap [Figures 6] is based on this muscle and can be harvested along with a skin paddle using a vertical or transverse incision. Alternatively, the muscle can be used on its own with an overlying split-skin graft. The rectus muscle flap is commonly used for sternal coverage in the lower part of the sternum and is based on the superior (Coleman and Bostwick, 1989; Grevious et al, 2018). Fernando et al (1998) reported that the flap can be raised solely on the eighth intercostal perforator, and Pantelides et al (2013) reported an advancement modification based on the deep inferior epigastric artery in salvage situations. The rectus abdominis is useful for inferior sternal defects and can be used in isolation or along with pectoralis major flaps. Literature reports a 50% is a risk of abdominal hernia following rectus abdominis flaps. However, Davison et al (2007) have shown a significant reduction of herniation to 2% when leaving the posterior rectus sheath intact and transposing muscle only.

The latissimus dorsi is a large flat muscle in the back that normally helps with activities that involve the shoulder girdle such as climbing and swimming. The latissimus muscle flap [Figure 7] was originally used for head and neck reconstruction by Quillen in 1978 and for microvascular free tissue transfer in 1979.

This flap represents a reliable voluminous flap for covering deep sternal wound defects. The large skin island can close significantly large defects, whilst allowing primary closure of donor defects. However, the latissimus dorsi flap is not as commonly used as the pectoralis or the rectus muscle flaps since these are in closer vicinity to the sternum. This flap is considered to be the workhorse mainly for large chest wall defects or salvage situations. It has low donor site morbidity and favourable discrete scars. Temporary shoulder weakness has been reported in literature and is

evident in the first few months after surgery (Lee, 2014).

## Omental flap

The greater omentum is a connective tissue structure found in the abdomen that has a role in combating infection and adhesions within the abdomen. The omental flap [Figure 8a and b] is vascularised via omental branches of the gastroepiploic artery and the flap is based on the right omental artery. The versatility of the omentum enables coverage of irregular defects as it contours into a deep sternal recess and has inherent resistance to infection, thereby reducing sepsis-related morbidity (Yasuuru, 1998). To circumvent the need for a laparotomy, laparoscopic harvest of omental flap have gained popularity. However, laparoscopic omental harvest should be used with caution in patients with significant cardiac dysfunction (El-Muttardi, 2013). As there is no option for a cutaneous island as part of the flap, skin grafting is usually required as part of the procedure.

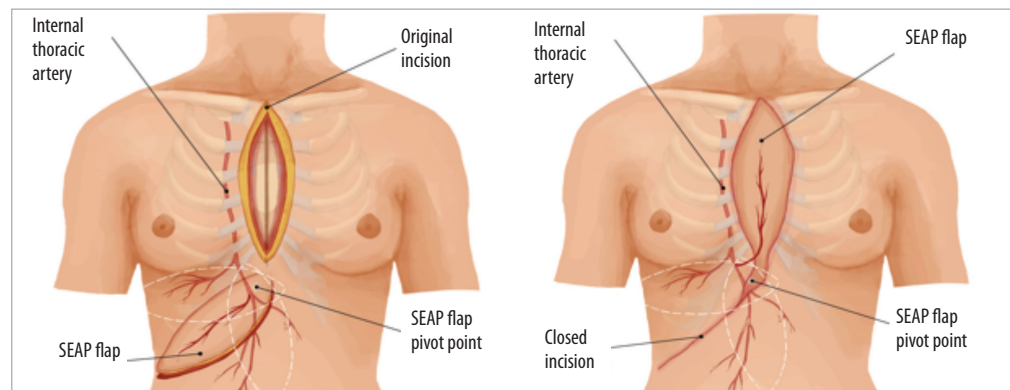
## Perforator flaps

The introduction of perforator flaps has been a major breakthrough in reconstructive surgery. The concept of perforator flaps [Figure 9a and b] has evolved from conventional flaps, whereby the harvested flap is based on arterial perforators that are located close to the flap surface and can be located using a hand-held acoustic Doppler (Saint-Cyr et al, 2009). This minimally invasive technique involves skin and subcutaneous tissue (Fasciocutaneous) harvest whilst sparing the source artery and underlying muscles. The axis of the flap is drawn and flap rotated into defect as required. Internal mammary artery perforator flaps (IMA) and superior epigastric artery perforator (SEAP) flaps have been successfully used in sternal wound reconstruction.

The IMA perforator flap was initially described for the closure of tracheostomy defects and since gained use in mastectomy defects (Takeuchi et al, 2013).

Kannan et al (2016) described their experience with using internal mammary artery perforator flaps for select cases of sternal and mediastinal defects. The IMA flap is usually based on the second or third internal mammary artery and can be raised as a fasciocutaneous flap or as a composite flap with underlying pectoralis muscle for deeper sternal defects from notch to xiphoid level. Second or third intercostal perforators are usually preserved during internal mammary harvest for coronary artery bypass graft surgery.

Kannan's results indicate that IMA



**Figure 9.** Possible SEAP flap design orientations based on the perforators [a]. Flap inset and donor site closure [b]

musculocutaneous flaps are less at risk of flap necrosis, possibly due to the larger calibre of deep perforator and less torsion on the perforator when rotating into defect. The supraclavicular scar is less desirable, especially in women.

The deep superior epigastric perforator flap has been described for the sternal wound defects. The flap is based on the single deep perforator of epigastric artery and can be rotated 90 degrees as a propeller flap to fill large defects (diagram), including the lower two-thirds of the sternum. The advantage of this flap is ease of dissection with minimal donor morbidity and, a favourable scar that is well hidden in the infra-mammary fold (Eburdery et al, 2016).

In summary, perforator flaps are useful alternatives for the reconstruction of sternal defects, especially in comorbid patients who cannot tolerate complex procedures. Pre-operative CT angiography is key to ensure the viability of source and perforator vessels.

### Bony union and reconstruction

To achieve complete healing of a complicated sternal wound, effective rigid closure of the sternum must be achieved to ensure the optimum environment for healing and to prevent long-term complications. The constant motion and stress placed on the sternum make it a difficult area for bony healing (Voss et al, 2008). This can lead to respiratory insufficiency, chronic pain and instability if a sound bony union is not achieved (Chepla et al, 2011). The aim of sternal fixation is to achieve close opposition of the sternal edges with minimal movement to allow the best environment for primary bone healing to occur (Voss et al, 2008; Grevious et al, 2018).

The traditional approach to achieving fixation of the sternum is sternal wiring. However, since wires can break, cut out, loosen or cause skin problems, more recently, sternal fixation using rigid titanium plating has been introduced. With

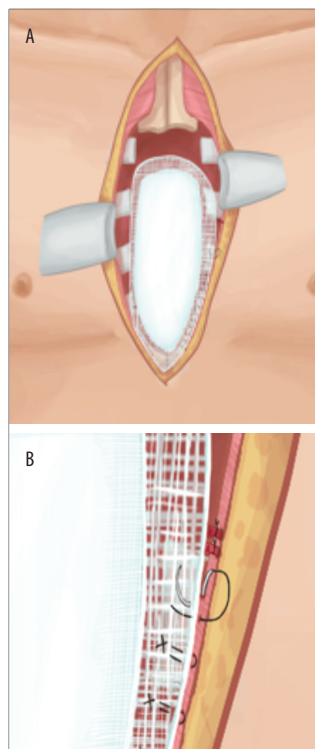
this technique, a lower rate of sternal wound infections and a lower incidence of non-union has been demonstrated (Cicilioni et al, 2005; Voss et al, 2008).

Another alternative is the use of Dall-Miles cables (Stryker) that are thicker than traditional sternal wires and are tensioned using special equipment. They can be tensioned more accurately than traditional sternal wires and they are less prone to breakage and cutting into bone. They are also less expensive than sternal plates (Eich and Heinz, 2000).

Literature suggests that rigid fixation of the sternum using plating techniques is superior to traditional wiring techniques (Voss et al, 2008). Plates, consisting of rigid titanium with locking screws, can be applied transversely or longitudinally (Cicilioni et al, 2005; Voss et al, 2008). Plate stabilization is achieved on the anterior surface of the ribs without the need of dissection at the deep aspect of the sternum, thereby avoiding the risk to the underlying structures. These allow primary closure or flap reconstruction to be performed on a stable base with reduced wound tension (Cicilioni et al, 2005).

When sternal non-union occurs alone or as part of dehiscence, removal of any existing fixation devices followed by debridement of devitalised and scar tissue and re-fixation is the treatment of choice. This can involve re-wiring or plate fixation. One established method is the Robicsek wiring technique that involves passing wires parasternally and weaving them between the ribs, and reinforcing this further with 'figure-of-eight' wires passed across the sternal halves (Robicsek et al, 1977). Modification and variation of the Robicsek wiring technique as well as other novel techniques for closure have been subsequently described (Losanoff et al, 2001a).

When there is extensive osteomyelitis of the sternum, fixation may not be possible, or, in cases where metalwork has become infected, resection



**Figure 10.** PMMA placement for chest wall defect [a]. Mesh contoured and sutured to chest wall edge [b]

of a portion of the sternum may be required. If the manubrium can be preserved and stabilised, patients often have no major functional deficit (Douville et al, 2004; Grevious et al, 2018).

Sternal defects more than 5 cm benefit from skeletal reconstruction to protect underlying structures and avoid paradoxical chest wall movements. Options include alloplastic materials, which consist of absorbable and non-absorbable mesh/composite implants. Composite mesh constructs contour the defect and provide stability. The most commonly used composite method is polypropylene mesh and polymethylmethacrylate (PMMA). The PMMA is sandwiched between two layers of polypropylene mesh and an exothermic reaction ensues whilst the PMMA cures. Vital structures should be protected from heat whilst this process takes place [Figure 10a and b] (Bibas et al, 2006).

## Conclusion

Sternal wound complications exist on a spectrum of severity but, fortunately, a large proportion heals with appropriate conservative management. Most superficial dehiscence heals with regular dressings and good wound care, but major or complicated sternal wound dehiscence require a multidisciplinary approach.

All risk factors should be addressed before median sternotomy surgery, especially in patients in the high-risk group. Careful patient selection and meticulous surgical technique are essential to prevent complications. Postoperatively, diligent observations for any early signs of wound breakdown or infection are vital to ensure optimal outcomes.

**WAS**

## References

Abu-Omar Y, Kocher GJ, Bosco P et al (2017) European Association for Cardio-Thoracic Surgery expert consensus statement on the prevention and management of mediastinitis. *Eur J Cardiothorac Surg* 51(1): 10–29

Agarwal JP, Ogilvie M, Wu LC et al (2005) Vacuum-assisted closure for sternal wounds: a first-line therapeutic management approach. *Plast Reconstr Surg* 116(4): 1035–40

Aratari C, Manché A, Ferretti L et al (2009) Cardiopulmonary bypass line sternal wrapping for protection and haemostasis. *Interact CardioVasc Thorac Surg* 9: 147–9

Berdajs DA, Trampuz, Ferrari E et al (2011) Delayed primary versus late secondary wound closure in the treatment of post-surgical sternum osteomyelitis. *Interact CardioVasc Thorac Surg* 12(6): 914–8

Bibas BJ, Bibas RA (2006) Operative stabilization of flail chest using a prosthetic mesh and methylmethacrylate. *Eur J Cardio Thorac Surg* 29(6): 1064–66

Castelló J, Centella T, Garro L et al (1999) Muscle flap reconstruction for the treatment of major sternal wound infections after cardiac surgery: a 10-year analysis. *Scand J Plast Reconstr Surg Hand Surg* 3(1): 17–24

## Acknowledgment

I would like to thank David Buckley, Graphics Designer at Manchester University NHS Trust, for the medical illustrations in this article.

Chaudhuri A, Shekar K, Coulter C (2012) Post-operative deep sternal wound infections: making an early microbiological diagnosis. *Eur J Cardiothorac Surg* 41: 1304–8

Chowdhary SA, Wilhelmi BJ (2019) Comparing Negative Pressure Wound Therapy with Instillation and Conventional Dressings for Sternal Wound Reconstructions. *Plast Reconstr Surg Glob Open* 7(1): e2087

Chepla KJ, Salgado CJ, Tang CJ et al (2011) Late Complications of Chest Wall Reconstruction: Management of Painful Sternal Nonunion. *Semin Plast Surg* 25(1): 98–106

Cicilioni OJ, Stieg FH, Papanicolaou G (2005) Sternal wound reconstruction with transverse plate fixation. *Plast Reconstr Surg* 115(5): 1297–303

Coleman JJ, Bostwick J (1989) Rectus abdominus muscle-myo-cutaneous flap for chest wall reconstruction. *Surg Clin North Am* 69(5): 1007–27

Davison SP, Clemes MW, Armstrong D et al (2007) Sternotomy wounds: rectus flap versus modified pectoral reconstruction. *Plast Reconstr Surg* 120: 929–34

Douville EC, Asaph JW, Dworkin RJ, et al (2004) Sternal preservation: a better way to treat most sternal wound complications after cardiac surgery. *Ann Thorac Surg* 78(5): 1659–64

Eburdery H, Grolleau JL, Berthier C, et al (2016) Management of large sternal wound infections with the superior epigastric artery perforator flap. *Ann Thorac Surg* 101: 375–7

Eich BS, Heinz TR (2000) Treatment of sternal nonunion with the Dall-Miles cable system. *Plast Reconstr Surg* 106(5): 1075–8

El-Muttardi N, Jabir S, Win TS (2013) Pearls and pitfalls of laparoscopic harvest of omental flap for sternal wound reconstruction in patients with significant cardiac dysfunction. *Plast Reconstr Aesthet Surg* 66(12): e394–5

El Oakley RM, Wright JE (1996) Postoperative mediastinitis: Classification and management. *Ann Thorac Surg* 61(3): 1030–6

Falor WH, Traylor R (1982) Extended indications for the median sternotomy incision. *Am Surg* 48(11): 582–3

Farhat F, Metton O, Jegaden O (2004) Benefits and complications of total sternotomy and ministernotomy in cardiac surgery. *Surg Technol Int* 13: 199–205

Fernando B, Myszynski C, Mustoe T (1988) Closure of a sternal defect with the rectus abdominis muscle after sacrifice of both internal mammary arteries. *Ann Plast Surg* 21: 468–471.

Fu RH, Weinstein AL, Chang MM et al (2016) Risk factors of infected sternal wounds versus sterile wound dehiscence. *J Surg Res* 200(1): 400–7

Greig AV, Geh JL, Khanduja V, Shibu M (2007) Choice of flap for the management of deep sternal wound infection — an anatomical classification. *J Plast Reconstr Aesthet Surg* 60(4): 372–8

Grevious MA, Ramaswamy R, Henry GI (2018) *Sternal Dehiscence Reconstruction Treatment & Management*. Available online at: <http://emedicine.medscape.com/article/1278627-overview> (accessed 20 April 2020)

Gualdi GF, Bertini L, Colaiacomo MC et al (2005) Imaging of median sternotomy complications. *Clin Ter* 156(1–2): 19–22

Hehr JD, Hodson TS, West JM, et al (2019). Instillation negative pressure wound therapy: An effective approach for hardware salvage. *Int Wound J*: 1–7

Horan TC, Gaynes RP, Martone WJ, et al (1992). CDC definitions of nosocomial surgical site infections, 1992:



- a modification of CDC definitions of surgical wound infections. *Infect Control Hosp Epidemiol* 13(10): 606–8
- Jones G, Jurkiewicz MJ, Bostwick J, et al (1997) Management of the infected median sternotomy wound with muscle flaps: the Emory 20-year experience. *Ann Surg* 225(6): 766–76
- José R, Castelló JR, Centella T, et al (1999) Muscle flap reconstruction for the treatment of major sternal wound infections after cardiac surgery: a 10-year analysis. *Scand J Plast Reconstr Surg Hand Surg* 33(1): 17–24
- Julian OC, Lopez-Bello M, Dye WS, et al (1957) The median sternal incision in intracardiac surgery with extracorporeal circulation: a general evaluation of its use in heart surgery. *Surgery* 42: 753–61
- Jurkiewicz MJ, Arnold PG (1977) The omentum: an account of its use in the reconstruction of the chest wall. *Ann Surg* 185(5): 548–54
- Jurkiewicz MJ, Bostwick J, Hester TR, et al (1980) Infected median sternotomy wound. Successful treatment by muscle flaps. *Ann Surg* 191(6): 738–44
- Kim P, Attinger C, Crist B, et al (2015) Negative pressure wound therapy with instillation: review of evidence and recommendations. *Wounds* 27(12): S2–S19
- Kim P, Attinger C, Oliver N, et al (2015) Comparison of outcomes for normal saline and an antiseptic solution for negative-pressure wound therapy with instillation. *Plast Reconstr Surg* 136(5):657e–664e
- Kotnis-Gaska A, Mazur P, Olechowska- Jarzab et al (2018) Sternal wound infections following cardiac surgery and their management: a single-centre study from the years 2016-2017 *Kardiocir Torakochirurgia Pol* 15(2): 79–85
- Lazar HL, Vander Salm T, Orgill D et al (2016) Prevention and management of sternal wound infection. *J Thorac Cardiovasc Surg* 152: 962–72
- Lee AB Jr, Schimert G, Shaktin S, Seigel JH (1976) Total excision of the sternum and thoracic pedicle transposition of the greater omentum; useful strategies in managing severe mediastinal infection following open heart surgery. *Surg* 80(4): 433–6
- Lee KT, Mun GH (2014) A systematic review of functional donor-site morbidity after latissimus dorsi muscle transfer. *Plast Reconstr Surg* 134 (2): 303–14
- Leung BK, LaBarbera LA, Carroll CA, et al (2010) The effects of normal saline instillation in conjunction with negative pressure wound therapy on wound healing in a porcine model. *Wounds* 22(7): 179–87
- Listewnik MJ, Jedrzejczak T, Majer K, Szylińska et al (2019) Complications in cardiac surgery: An analysis of factors contributing to sternal dehiscence in patients who underwent surgery between 2010 and 2014 and a comparison with the 1990–2009 cohort. *Adv Clin Exp Med* 28(7): 913–22
- Losanoff JE, Jones JW, Richman BW (2002) Primary closure of median sternotomy: techniques and principles. *Cardiovasc Surg* 10(2): 102–10
- Losanoff JE, Richman BW, Jones JW (2002) Disruption and infection of median sternotomy: a comprehensive review. *Eur J Cardiothorac Surg* 21(5): 831–9
- Malmström M, Ingemansson R, Sjögren J (2007) Mechanisms governing the effects of vacuum-assisted closure in cardiac surgery. *Plast Reconstr Surg* 120(5): 1266–75
- Maxwell GP (1980) Iginio Tansini and the origin of the latissimus dorsi musculocutaneous flap. *Plast Reconstr Surg* 65: 686–92
- McDonald WS, Brame M, Sharp C, Eggerstedt J (1989) Risk factors for median sternotomy dehiscence in cardiac surgery. *South Med J* 82(11): 1361–4
- Miller JL, Nahai F (1989) Repair of the dehiscid median sternotomy incision. *Sur Clin North Am* 69(5): 1091–2
- O'Brien Norris S (1995) *Sternal Wound Infection: Guidelines for Critical Care Nursing*. Mosby, Oxford
- Pairolero PC, Arnold PG (1984) Management of recalcitrant median sternotomy wounds. *J Thorac Cardiovasc Surg* 88(3): 357–64
- Pantelides NM, Young SS, Iyer S (2017) The rectus abdominis muscle advancement flap as a salvage option for chest wall reconstruction. *Ann R Coll Surg Engl* 99 (5): e142–e144
- Public Health England (2019) *Surveillance of surgical site infections in NHS hospitals in England, 2018/19*. Available at: [https://assets.publishing.service.gov.uk/government/uploads/system/uploads/attachment\\_data/file/854182/SSI\\_Annual\\_Report\\_2018\\_19.pdf](https://assets.publishing.service.gov.uk/government/uploads/system/uploads/attachment_data/file/854182/SSI_Annual_Report_2018_19.pdf) (accessed on 20 April 2020)
- Quillen CG, Shearin JC, Georgiade NG (1978) Use of the latissimus dorsi myocutaneous island flap for reconstruction in the head and neck area: case report. *Plast Reconstr Surg* 62(1): 113–7
- Robicsek F, Daugherty HK, Cook JW (1977) The prevention and treatment of sternum separation following open heart surgery. *Coll Works Cardiopulm Dis* 21: 61–3
- Rupprecht L, Schmid C (2013) Deep sternal wound complications: an overview of old and new therapeutic options. *Open J Cardiovasc Surg* 13(6): 9–19
- Sahasrabudhe P, Jagtap R, Waykole P et al (2011) Our experience with pectoralis major flap for management of sternal dehiscence: A review of 25 cases. *Indian J Plast Surg* 44(3): 405–13
- Saint-Cyr M, Wong C, Schaverien M, et al (2009) The perforasome theory: vascular anatomy and clinical implications. *Plast Reconstr Surg* 124: 1529–44
- Shumacker HB, Mandelbaum I (1963) Continuous antibiotic irrigation in the treatment of infection. *Arch Surg* 86: 384
- Singh DP, Gowda AU, Chopra K, et al (2017). The effect of negative pressure wound therapy with antiseptic instillation on biofilm formation in a porcine model of infected spinal instrumentation. *Wounds* 28(6):175–180
- Sjögren J, Malmström M, Gustafsson R, Ingemansson R (2006) Poststernotomy mediastinitis: a review of conventional surgical treatments, vacuum-assisted closure therapy and presentation of the Lund University Hospital mediastinitis algorithm. *Eur J Cardiothorac Surg* 30(6): 898–905
- Song DH, Wu LC, Lohman RF, Gottlieb LJ, Franczyk M (2003) Vacuum assisted closure for the treatment of sternal wounds: the bridge between debridement and definitive closure. *Plast Reconstr Surg* 111(1): 92–7
- Takeuchi M, Sakurai H (2013) Internal mammary artery perforator flap for reconstruction of the chest wall. *J Plast Surg Hand Surg* 47: 328–30
- Tobin GR (1989) Pectoralis major muscle-myocutaneous flap for chest wall reconstruction. *Surg Clin North Am* 69(5): 991–1006
- Tizian C, Borst HG, Berger A (1985) Treatment of total sternal necrosis using the latissimus dorsi muscle flap. *Plast Reconstr Surg* 76(5): 703–7
- Voss B, Bauerschmitt R, Will A et al (2008) Sternal reconstruction with titanium plates in complicated sternal dehiscence. *Eur J Cardiothorac Surg* 34(1): 139–45
- West J, Jordan S, Mendel E et al (2018) Instillation negative pressure wound therapy: an effective tool for complex spine wounds. *Adv Wound Care* 7: 333–38
- Yasuura K, Okamoto H, Morita S, et al (1998) Results of omental flap transposition for deep sternal wound infection after cardiovascular surgery. *Ann Surg* 227: 455–9