

Evaluating the outcomes of eight patients with diabetic foot ulcers using a new topical oxygen delivery device



Author:
Harikrishna KR Nair

Oxygen has long been acknowledged as playing a significant role in wound healing (Gordillo and Sen, 2003). This article looks at the impact of increased oxygenation on wound healing through a case series of eight patients commenced on NATROX® therapy after presenting with a non-healing diabetic foot ulcer (DFU) despite receiving a good standard of care – regular debridement, off-loading and regular dressing. The device, which is lightweight and discreet, helped to promote patient concordance and proved to be an effective therapy option, resulting in extremely positive patient outcomes.

D iabetes is likely to be the biggest epidemic in human history. Its impact on global health has previously been significantly underestimated, with both the International Diabetes Federation and World Health Organization stating in 2000 that diabetes would affect between 324 million and 366 million people by 2030, a prediction that was exceeded by 2015 (World Health Organization, 2016). As the prevalence of diabetes grows, so does the occurrence of complications associated with this condition; particularly where lifestyle has been a contributing factor to the development of diabetes. One such complication is diabetic foot disease, which affects around 25% of the diabetic population and is the leading cause of non-traumatic amputations of the lower limb (Armstrong et al, 2017). Hence this particular complication is a major healthcare and socioeconomic burden (Wu et al, 2007). Identifying a simple, efficacious and cost-effective ways of managing patients with foot ulcers is therefore imperative.

It is estimated that 422 million (8.5%) of the world's adult population has diabetes (Wu et al, 2007). Malaysia has an even greater prevalence; in 2014, it was estimated that 2.6 million Malaysians had diabetes, which equates to over 15% of the total population (Lam et al, 2014). As people with diabetes have a one-in-four risk of developing a diabetic foot ulcer (DFU) in their lifetime, proactive management is crucial (Armstrong et al, 2017). Around 50% of DFUs become infected, and approximately 20% of these infected wounds

will lead to the patient having an amputation (Wu et al, 2007). Furthermore, patients with diabetes are twice as likely to have peripheral arterial disease (PAD) as those without diabetes (Wounds International, 2018). In the presence of a wound, PAD and diabetes will impact negatively on the likely outcomes of wound treatment, including (Armstrong et al, 2011):

- ▶ Significantly lower probability of healing
- ▶ Longer healing times
- ▶ Higher probability of recurrence
- ▶ Higher probability of wound infection
- ▶ Greater risk minor and major amputations
- ▶ Potentially higher mortality.

Almost every step in the wound healing process is critically dependent on oxygen availability. Oxygen is an essential building block for the synthesis of cellular energy, cellular division, and protein production. By creating an oxygen-rich environment, cellular energy resources are increased 18-fold (Lordish et al, 2000). It is also essential for both the building of collagen and the strengthening (cross-linking) of this key structural protein.

Collagen, the most abundant protein in the body. It provides strength, integrity and structure to tissues. When a wound disrupts tissues, collagen is needed for repair and restoration of anatomic structure and function. If an insufficient amount of collagen is deposited, the new tissue is weak and could break down (Diegelmann and Evans, 2004).

Collagen deposition and tensile strength are both limited by tissue oxygen tension in wound tissue (Jonsson et al, 1991). Bacteria

Harikrishna KR Nair is
Head and Consultant of
Wound Care Unit, Department
of Internal Medicine, Kuala
Lumpur Hospital, Malaysia

tend to be prevalent in chronic wounds and significantly delay wound healing, especially in cases of infection (Edward and Harding, 2004). The bacterial killing capacity of these cells is greatly impaired at the low pO_2 found in hypoxic wounds (Allen et al, 1997). In hypoxic wounds, the oxygen consumed while clearing microorganisms further reduces the oxygen available for other cellular wound healing processes. Furthermore, chronic or severe hypoxia interferes with the angiogenic process, stifling new vessel development (Hopf et al, 2005). Without oxygen, wound healing simply cannot occur.

An obvious way to improve clinical outcomes in hypoxic wounds is to improve blood flow; however, many patients with DFUs are not good candidates for revascularisation surgery due to complications arising from comorbidities, late presentation or chronic ischaemia associated with irreversible tissue injury (Yu et al, 2016). Even if revascularisation is achieved, wound healing can still be challenging. Emerging evidence suggests that topical oxygen therapy may provide a novel solution.

THE USE OF NATROX IN NON-HEALING WOUNDS

Clinical evidence generated so far shows that NATROX has had a significant positive impact on challenging and previously non-healing

wounds. A randomized controlled trial of 20 hard-to-heal DFUs (mean wound duration prior to the study was 6.5 months) demonstrated powerful effects of an 8-week course of NATROX therapy on wound size and wound healing (Yu et al, 2016). All patients received standard of care with weekly wound irrigation, sharp debridement and off-loading when required. Overall, 90% of NATROX-treated wounds healed during this 8-week study compared to 30% of wounds treated with standard care.

A 10-patient pilot study of hard-to-heal DFUs, also treated with NATROX for 8-weeks, had similar findings (Hayes et al, 2017). Mean wound duration prior to this study was 43 weeks and 50% of patients had documented PAD. After 8 weeks of NATROX treatment, mean ulcer size was reduced by 51%, on average. Some of the 10 patients responded especially well to the topical oxygen therapy. One patient's ulcer, which had been present for 88 weeks, had reduced to 10% of baseline size by the end of the 8-week NATROX trial. Another patient, who had been offered amputation as a result of their wound, saw the wound size shrink to 30% of baseline in just 8 weeks (Hayes et al, 2017).

An observational study of 100 chronic wounds reported wound closure across a range of hard-to-heal wound types (Kaufmann et al, 2018). Mean wound duration prior to NATROX therapy was 15.2 months. This study demonstrated complete wound healing in 57% of DFUs and arterial ulcers when treated with NATROX for longer than 25 days. The authors concluded that NATROX oxygen therapy transitioned wounds from a non-healing to a healing state (Kaufmann et al, 2018).

Due to the high prevalence of diabetes in Malaysia and the high number of DFUs presenting at the wound clinic, a small pilot study was undertaken to assess the effectiveness of portable topical oxygen therapy in healing previously non-healing DFUs and the practicalities of implementing such therapy.

METHODOLOGY

The case series involved eight patients selected from the current caseload. All participants had a non-healing DFU of at least 2 months' duration, despite receiving a good standard of care, which consisted of regular debridement, off-loading where appropriate, and regular dressing changes with irrigation solution and dressing selection dictated by the

Figure 1. The three main components of the NATROX Oxygen Wound Therapy device

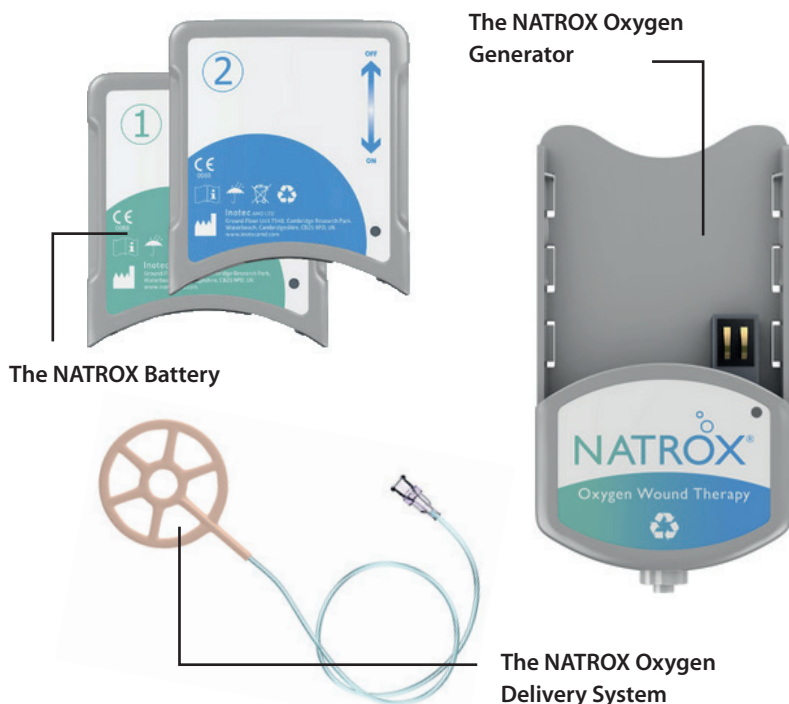


Table 1. Patient demographics

Patient	Sex	Age	Type of diabetes	Smoker
1	Male	48	Type 2	No
2	Male	81	Type 2	No
3	Male	61	Type 2	No
4	Male	58	Type 2	No
5	Male	48	Type 1	No
6	Male	75	Type 2	No
7	Male	56	Type 1	No
8	Male	49	Type 1	Yes

Table 2. Clinical details of ulceration on commencing NATROX

Patient	Severity	Duration	Wound Size
1	3	2 months	7.5 x 3.5 cm
2	3	2 months	4.5 x 3.5 cm
3	4	6 months	9.0 x 6.0 cm
4	4	3 months	6.5 x 3.8 cm
5	3	2 months	8.0 x 5.0 cm
6	3	24 months	1.5 x 1.5 cm
7	4	2 months	6.0 x 3.0 cm
8	4	48 months	4.0 x 2.0 cm

appearance and needs of the wound.

Having obtained consent, patients deemed suitable were commenced on NATROX Oxygen Wound Therapy (OWT) device. This device is designed to deliver 98% pure humidified oxygen directly to the wound bed at a continuous rate of 13 ml per hour (Inotec, 2006). It is compact and battery-operated, making it completely portable. The system is intended for use in complex, slow-healing or non-healing wounds, which typically have low wound oxygen levels. The device can be used in combination with most types of secondary dressings. The use of NATROX OWT has been shown to reduce pain in the majority of patients and stimulate healing in complex, hard-to-heal wounds.

The system consists of three main components [Figure 1]:

The NATROX Oxygen Generator (OG)

- ▶ Small completely portable device
- ▶ No ON/OFF switch; activation occurs when a fully charged battery is fitted
- ▶ Flashing green light indicates oxygen is flowing.

The NATROX Battery

- ▶ Two batteries are supplied
- ▶ One is fitted to the NATROX device while

the other is left on continuous charge

- ▶ Fully-charged battery will power the OG for at least 24 hours.

The NATROX Oxygen Delivery System (ODS)

- ▶ Sterile, single-use ODS.
- ▶ Connects to the OG providing oxygen directly to the wound bed.
- ▶ Soft and highly conformable

The ODS requires a secondary dressing to hold it in place. It works with all occlusive or semi-occlusive dressings; the choice of dressing is dictated by the level of exudate and condition of the wound.

All eight patients commenced on NATROX were male. The patients ages ranged from 48 to 81 years old, with the average age being 60 [Table 1].

A severity grading system, which had been adapted from the Wagner Ulcer Classification System (Wagner and Meggitt, 1981), was used:

- ▶ Level 1 was defined as superficial ulceration
- ▶ Level 2 as deeper ulceration
- ▶ Level 3 as a deep ulcer with bone involvement
- ▶ Level 4 as gangrene/previous amputation.

All the ulcers treated were in higher categories of severity and had been present for at least 2 months; two patients had ulcers that had been present for longer than a year [Table 2]. DFUs carry a risk of infection and all eight patients in this study had previously been treated for an infection, with most wounds still showing signs of an unhealthy bioburden.

Application of NATROX

The NATROX ODS was applied directly to the wound and covered with a superabsorbent dressing, as an increase in exudate is normally reported in the first couple of weeks. Patients were given verbal and pictorial instructions on how to charge and change the battery. They were also informed to check the device on a regular basis, making sure that the green indicator light was flashing to confirm oxygen was flowing. Initially, wound dressings were changed twice weekly. As wound healing progressed, this was reduced to weekly.

RESULTS

Photographs of the wounds were taken before NATROX OWT was started and when treatment was stopped [Figure 2]. NATROX was used for between 6 and 18 weeks [Figure

Figure 2. Clinical photographs taken before and after NATROX Oxygen Wound Therapy

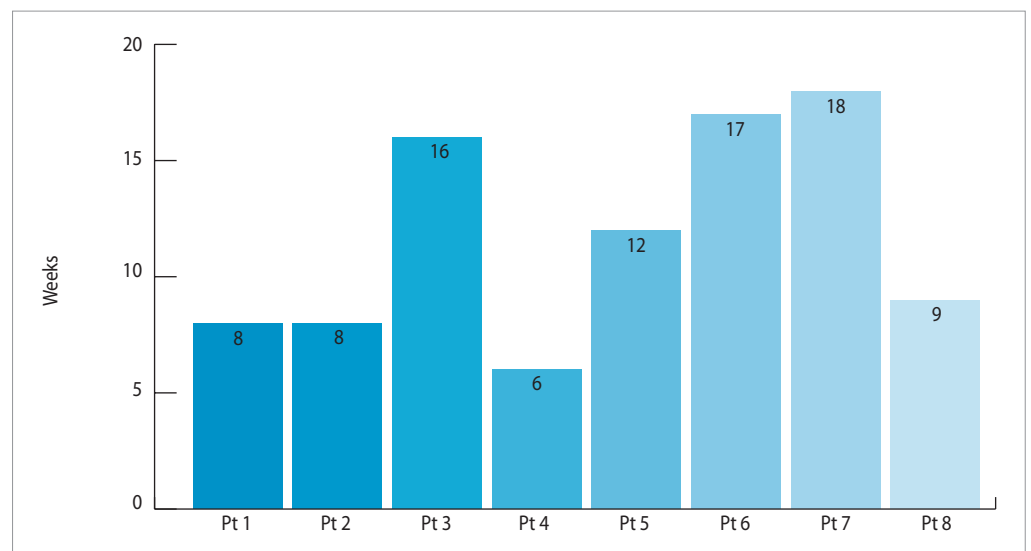
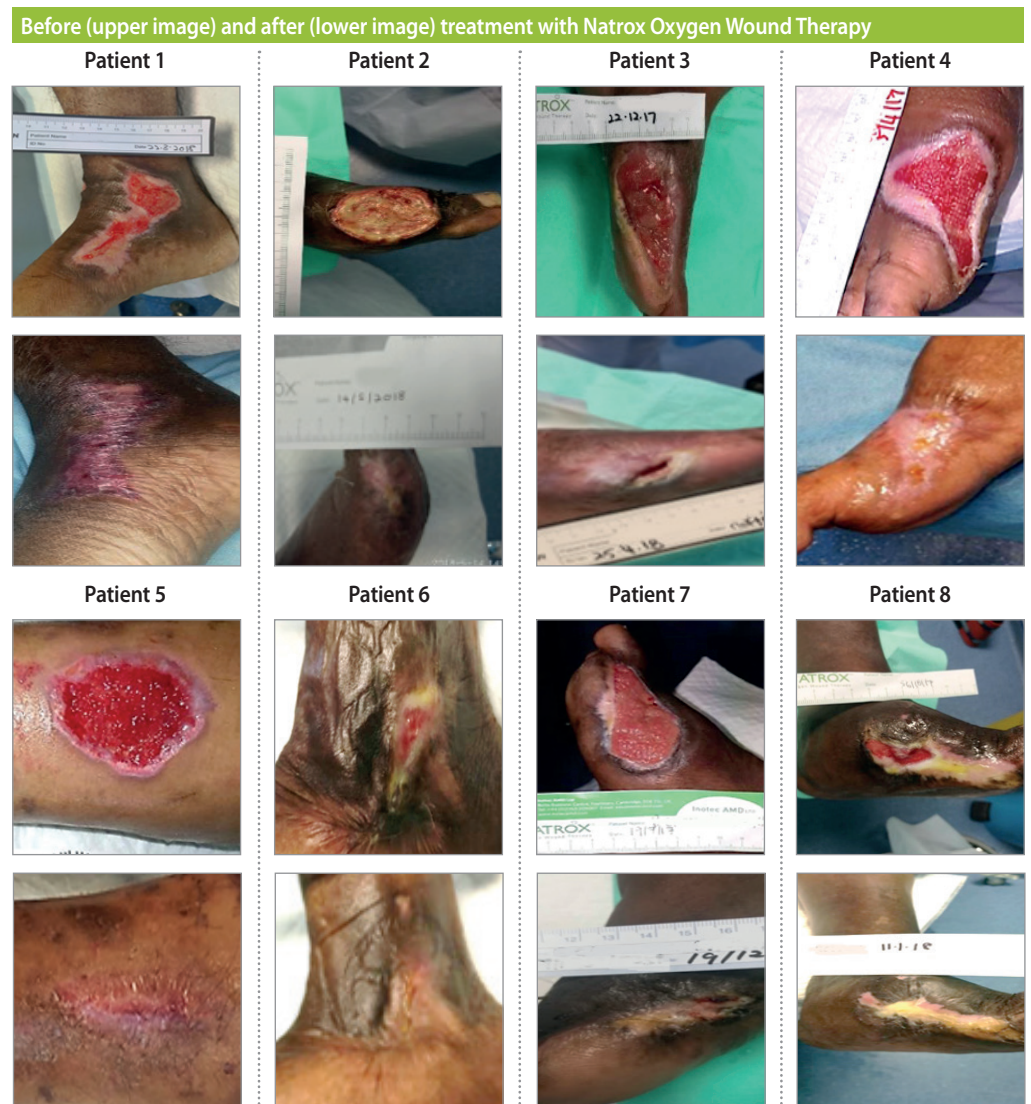

Figure 3. Duration of therapy

3], with an average of 11.7 weeks for the group.

Of the eight patients that utilized NATROX OWT, seven patients achieved complete healing (88%). Patient 3, whose DFU did not heal completely, achieved a 95% reduction in wound size.

No patient developed an infection while using NATROX. Where pain had been reported, the patients' pain levels had improved.

DISCUSSION

NATROX OWT is a simple, easy-to-manage device that patients with DFUs can use in their own homes. The easy-to-follow instructions on how to check oxygen flow and change the batteries mean that patients are put in charge and feel empowered and motivated to become active participants in their own care. The fact that the device is completely silent and 100% portable helps to ensure concordance during ongoing therapy, thus improving overall clinical outcomes.

The ability of NATROX to manage and heal complex and chronic wounds offers not only benefits to the patient and clinician but has the potential to offer health economic benefits as well. Healing wounds more swiftly will help free up precious resources and save money by reducing the amount materials, the number of clinic appointments and amount of time that clinicians spend managing chronic wounds. Chronic wound management is a growing problem globally. An ageing population coupled with poor lifestyle choices has seen obesity and type 2 diabetes reach epidemic levels, which in turn has led to significant increases in both the prevalence and incidence of chronic hard-to-heal wounds. More research is needed to assess the potential impact of NATROX on the proactive management of chronic wounds.

CONCLUSION

For this particular group of patients, NATROX was an extremely effective therapy option, healing 88% of wounds that had previously been deemed non-healing. It took no longer than the standard wound care protocol to manage NATROX therapy in the clinic. The frequency of dressing changes required was not dissimilar to the normal regimen. The ability to use the product with standard dressings meant that NATROX was very easy to adopt within the author's clinical practice and busy wound care clinics. During this small pilot study, there were

no adverse reactions to NATROX and no issues with its implementation. **WAS**

References

- Allen DB, Maguire JJ, Mahdavian et al (1997) Wound hypoxia and acidosis limit neutrophil bacterial killing mechanisms. *Arch Surg* 132(9): 991–96
- Armstrong DG, Cohen K, Courric S et al (2011) Diabetic foot ulcers and vascular insufficiency: our population has changed but our methods have not. *J Diabetes Sci Technol* 5(6): 1591–5
- Armstrong DG, Boulton AJM, Bus SA (2017) Diabetic foot ulcers and their recurrence. *New Eng J Med* 376(24): 2367–75
- Diegelmann RF, Evans MC (2004) Wound healing: an overview of acute, fibrotic and delayed healing. *Front Biosci* 9: 283–89
- Edwards R, Harding KG (2004) Bacteria and wound healing. *Curr Opin Infect Dis* 17(2): 91–6
- Hayes PD, Alzuhir N, Curran G et al (2017) Topical oxygen therapy promotes the healing of chronic diabetic foot ulcers: a pilot study. *J Wound Care* 26(11): 652–60
- Hopf HW, Gibson JJ, Angeles AP et al (2005) Hyperoxia and angiogenesis. *Wound Repair Regen* 13(6): 558–64
- Gordillo GM, Sen CK (2003) Revisiting the essential role of oxygen in wound healing. *Am J Surg* 186(3):259–63
- Inotec (2006) data on file
- Jonsson K, Jensen JA, Goodson WH et al (1991) Tissue oxygenation, anemia, and perfusion in relation to wound healing in surgical patients. *Ann Surg* 214(5): 605–13
- Kaufmann H, Gurevich M, Tamir E et al (2018) Topical oxygen therapy stimulates healing in difficult, chronic wounds: a tertiary centre experience. *J Wound Care* 27(7): 426–31
- Lam AWC, Zaim MR, Helmy HH, Ramdhan IMA (2014) Economic Impact of managing acute diabetic foot infection in a tertiary hospital in Malaysia. *Malaysian Orthopaedic Journal* 8(1): 46–49
- Lordish H, Berk A, Lawrence z et al (2000) *Molecular Cell Biology* 4th edn WH Freeman, New York
- Wagner FW, Meggitt BC (1981) The dysvascular foot: a system for diagnosis and treatment: *Foot Ankle* 2: 64–122
- World Health Organization (2016) *Global Report on Diabetes*. Available online at: http://apps.who.int/iris/bitstream/10665/204871/1/9789241565257_eng.pdf (accessed 6.12.2018)
- Wounds International (2018) *Consensus Round Table Meeting: Portable Topical Oxygen Therapy for Healing Complex Wounds*. Available at: <https://www.woundsinternational.com/resources/details/consensus-round-table-meeting-portable-topical-oxygen-therapy-for-healing-complex-wounds> (accessed 6.12.2018)
- Wu S, Driver VR, Wrobel JS et al (2007) Foot ulcers in the diabetic patient, prevention and treatment. *Vasc Health Risk Manag* 3(1): 65–76
- Yu J, Lu S, McLaren AM et al (2016) Topical oxygen therapy results in complete wound healing in diabetic foot ulcers. *Wound Repair Regen* 24(6): 1066–72