

## NATROX® — Let the topical oxygen flow for healing complex wounds



**Authors:**  
Tjun Y Tang,  
Tze T Chong,  
John CC Wang,  
Edward C Choke,  
Harikrishna  
KR Nair

Oxygen has a critical role in wound healing including the production of energy to fuel cell metabolism, angiogenesis, fight infection, collagen synthesis and re-epithelization. Natrox® represents a new development in topical oxygen therapy, as it provides a more practical and patient-friendly mode of delivery for oxygen therapy. It is lightweight, the size of a mobile phone and portable, and can provide continuous oxygen therapy to a wound. It is suitable for wearing under clothes during the day and can be positioned to be used comfortably at night, facilitating continuous use in a way that suits a patient's everyday lifestyle. The clinical evidence thus far suggests it can help heal chronic wounds such as diabetic foot and venous ulcers with high patient satisfaction. However, more research is required to help position this device in the wound healing arena and identify when it is indicated.

*Tjun Y Tang is Consultant Vascular and Endovascular Surgeon at the Department of Vascular Surgery, Singapore General Hospital; Tze T Chong is Head and Senior Consultant at Department of Vascular Surgery, Singapore General Hospital, Singapore; John CC Wang is Senior Consultant at Department of Vascular Surgery, Singapore General Hospital, Singapore; Edward C Choke is Consultant at SengKang General Hospital & Singapore General Hospital, Singapore; Harikrishna KR Nair is Head and Consultant at the Wound Care Unit, Department Internal Medicine, Hospital Kuala Lumpur, Malaysia*

**T**he presence of a wound increases the body's requirement for oxygen by 20% for a patient with a clean wound and by 50% for an infected wound (Dernling, 2009). Oxygen is critical to many of the processes required in wound healing including the production of energy to fuel cell function and metabolism, angiogenesis, collagen synthesis and cross-linking, epithelization and resistance to infection (Castilla et al, 2012).

Wound hypoxia is often multi-factorial and is due to either reduced oxygen delivery to tissues (systemic or local disease) and/or due to increased oxygen demands by wound tissues. Causes of reduced oxygen delivery to wound tissues include:

- Macrovascular disease — reduced arterial flow due to peripheral vascular disease or reduced diffusion of oxygen through oedematous tissue in venous disease
- Microvascular disease — capillary wall thickening and arterio-venous shunting with diabetes, fibrin deposition in chronic venous insufficiency and vasculitis
- Chronic wound inflammation — the presence of wound biofilm sets up a chronic inflammatory milieu where neutrophils and macrophages from the immune system consume oxygen leading to low wound oxygen state (James et al, 2016)

- Systemic disease, e.g. reduced arterial oxygen levels due to respiratory disease, heart disease or anaemia (Sen, 2009). Other factors that may contribute to tissue hypoxia include pulmonary disease, sympathetic dysregulation, hypothermia and haemodynamic instability requiring the need of vasopressors.

It is important to assess for underlying factors that contribute to tissue hypoxia whilst keeping in mind that chronic wounds are typically in a hypoxic state (Yip, 2015).

Wound hypoxia is an important initiator of wound healing but once healing has started, adequate levels of oxygen are required for healing to progress and for full re-epithelization (Yip, 2015). Persistent wound hypoxia, especially as a result of peripheral vascular disease can have a multitude of deleterious effects that delay healing and promote wound chronicity.

Research has found that many aspects of wound healing can be significantly increased when higher than normal levels of oxygen are present. Fibroblast proliferation and protein production are maximal at oxygen levels of 160 mmHg (Howard et al, 2013) and activity of a key collagen producing enzyme, prolyl hydroxylase is maximal at oxygen levels around 250 mmHg (Mussini et

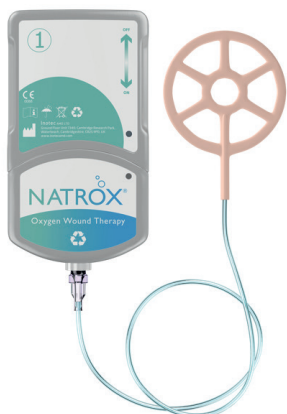

Figure 1. The Natrox® device

al, 1967). Chronic wounds have an oxygen level of 5–20 mmHg, which can go down to 0–5mmHg in devascularized regions (Howard et al, 2013). Wound cells convert to anaerobic at oxygen levels below 20 mmHg slowing the wound healing process (Howard et al, 2013). The concept of increasing the oxygen concentration in healing wounds developed originally with hyperbaric oxygen therapy (HBOT), and from the fact that oxygen is one of the most essential elements used during cellular metabolism. Poor tissue oxygenation, as is often seen in diabetic foot ulcers (DFU), is a significant impediment to cellular activity and is, therefore, very likely to impair wound healing. HBOT has shown only limited success because it is only possible to use it for very short periods of the week, limiting its efficacy in raising oxygen levels in wounds for a prolonged period (Margolis et al, 2013). For DFUs, 20–40 sessions of HBOT are required to show any significant change. In addition, access is difficult in many areas; it is also expensive and requires a considerable time commitment from the patient (Johnston et al, 2013). Therefore, an alternative technological solution to increasing oxygen levels is an exciting development for this expanding market.

### Natrox® Oxygen Wound Therapy System

Natrox® Oxygen Wound Therapy [Figure 1] was developed by Inotec AMD Limited (Cambridgeshire, UK) and employs a small battery-powered oxygen generator (OG) to concentrate atmospheric moist oxygen, at a rate of around 13 mL/hour through a fine, soft tube to a dressing-like oxygen delivery system (ODS), which is placed over the wound

and held in place by a conventional dressing. The oxygen concentrator generates 98% of the oxygen through the electrolysis of water, which is naturally present in the atmosphere. The energy produced by the battery creates a positive charge on one face of the membrane inside the OG and a negative charge on the other face. This charge then splits the hydrogen and oxygen that forms water, pulling the positive hydrogen ions one way and the negative oxygen ions in the opposite direction. The hydrogen ions then recombine with oxygen molecules from the air to form more water, which then splits again across the membrane. The oxygen ions combine in pairs to form oxygen molecules which accumulate and then start flowing down the tubing to the ODS. The OG is worn in a holster on the waist or above the calf or is placed in a trouser pocket, thus enabling the patient to enjoy normal mobility (hence ‘ambulatory’) while receiving continuous treatment. This mode of delivery compared to other topical oxygen therapies means that oxygen can be used in a more practical, patient-friendly and, therefore, better-tolerated way.

The oxygen delivered with the Natrox® device can even penetrate healthy skin and this is seen in Figure 2. It shows lower levels of oxygenated haemoglobin in blue and higher levels in red. The change in colour in panel 2B, when Natrox® has been turned on, shows that oxygen has penetrated far enough into the tissues to enter the capillary bed and bind to deoxygenated haemoglobin.

### The current clinical data for Natrox®

Addenbrooke’s Hospital in Cambridge, UK and St George’s Hospital in London, UK jointly carried out a 6-month case evaluation, involving 10 patients with chronic DFU who were studied using Natrox® for a period of 8 weeks (Hayes et al, 2017). The median duration of DFU before the intervention was 25 weeks. Seven out of 10 wounds showed healing trajectories evidenced by the decreasing area of the wound. Even when the non-responding wounds were included, the average decrease in wound area obtained by a regression analysis was 4.9% per week. The device was very well-received by both clinicians and patients alike, with patients giving it a median acceptability score of 9.9/10 for day use and 10/10 for night use. There was also a trend towards improved pain scores within the small cohort, which fell by almost a quarter over the course of the study. Although the

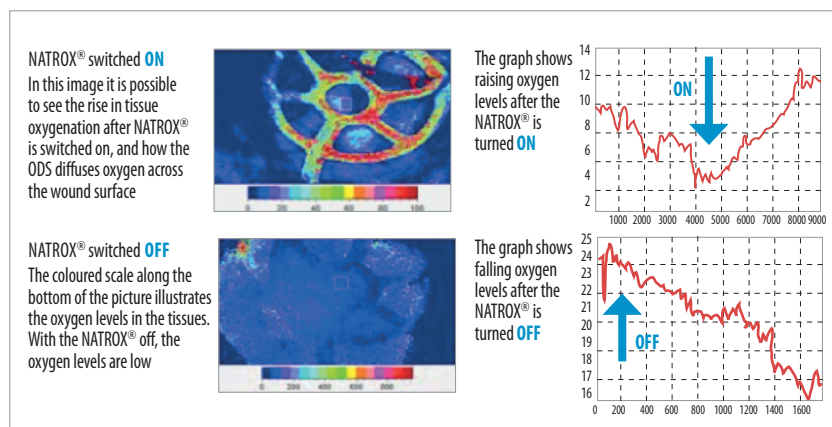
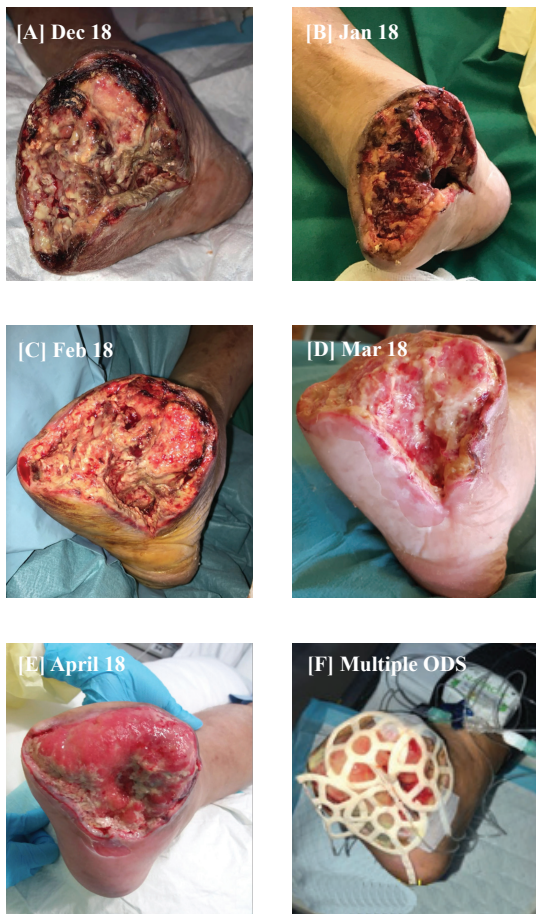
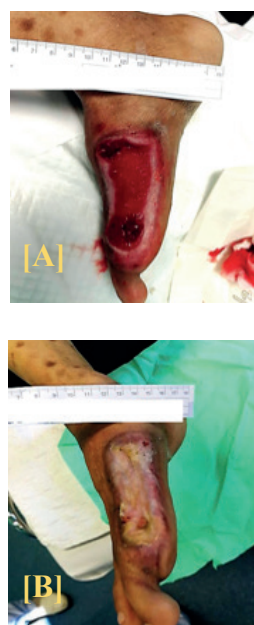

Figure 2. Oxygenated haemoglobin levels in healthy skin with Natrox® switched on (top pane) and off (bottom pane)



**Figure 3. Case Study 1**

A 55-year-old Chinese male who was known to be home ambulant with (poorly controlled) diabetes, hypertension, chronic kidney disease with a renal transplant for non-steroidal anti-inflammatory drugs induced nephropathy and on immunosuppression; prone to infections with multiple admissions for intravenous antibiotic treatment. The patient presented with a wet gangrene of his right 1st to 3rd toes (Rutherford 6). He underwent a forefoot amputation after lower limb revascularization with anterior tibial artery angioplasty (November 2017). Despite 5 weeks of gold standard of care, including multiple wound debridements and washouts [A], there were no signs of wound healing. NPWT was utilised to try and stimulate granulation tissue, however, the wound remained static. In January 2018, the wound bed was predominately sloughy with multiple areas of necrosis and no evidence of granulation tissue [B]. Due to the lack of progress and the high risk of further complications and infections, a transtibial amputation was considered the only realistic option. However, the patient was adamant that he did not want to lose his foot. After careful consideration and very limited choices, Natrox® oxygen wound therapy was commenced in an attempt to treat the local wound hypoxia and support the wound-healing processes. Over the next 4 weeks, Natrox® appeared to kick-start angiogenesis and there were signs of active granulation tissue [C]. By March, the wound bed was free of necrosis and there was minimal superficial slough present [D]. The wound bed and wound edge appeared much healthier in colour. Due to the significant improvement to the wound and also the reduction in pain reported by the patient, Natrox® was continued. By April, the wound bed was completely free from slough and the previous tissue deficit was well on the way to resolving [E]. Picture F shows the application of multiple operational deflection shapes over the large forefoot wound. The long-term goal is to graft the forefoot when the wound bed has been completely optimised.



**Figure 4. Case Study 2**

A 45-year old Malay gentleman with type 2 diabetes mellitus with oral hypoglycaemic agents failure and on insulin therapy, presented with a right gangrenous hallux. The glycaemic control was poor and he was put on a basal bolus regime and intravenous antibiotics to combat infections were started. Once his diabetic state was stabilised, an extended Ray amputation was performed, which resulted in an open wound. Gold standard of care was maintained for the next 4 weeks, however, during this time the wound failed to progress. At this time, the wound was deemed non-healing. Due to the high risks of further amputations associated with diabetic foot wounds, the clinic practices a very proactive approach to wound healing. Hence, following sharp debridement, continuous topical oxygen therapy (Natrox®) was commenced [A] with the goal to stimulate wound healing and achieve full wound closure quickly. Natrox® oxygen therapy was maintained for the next 31 days with significant improved noted [B] to the wound. On review, the wound had achieved over a 95% wound re-epithelialisation. Natrox® was discontinued at this time and the patient was returned to "normal" advanced wound dressings till complete wound closure was achieved. Initiating such a proactive approach to diabetic foot management achieved both clinical and economic benefits.

Dermling RH (2009) Nutrition, anabolism and the wound healing process: An overview. *Eplasty* 9:e9.

Hayes PD, Alzuhir N, Curran G, et al (2017) Topical oxygen therapy promotes the healing of chronic diabetic foot ulcers: a pilot study. *J Wound Care* 26(11): 652–60

Howard MA, Asmis R, Evans KK, et al (2013) Oxygen and wound care: a review of current therapeutic modalities and future direction. *Wound Repair Regen* 21(4): 503–11

James GA, Ge Zhao A, Usui M, et al (2016) Microsensor and transcriptomic signatures of oxygen depletion in biofilms associated with chronic wounds. *Wound Repair Regen* 24(2): 373–83

Johnston BR, Ha AY, Brea B et al (2016) The Mechanism of hyperbaric oxygen therapy in the treatment of chronic wounds and diabetic foot ulcers. *RI Med J* (2013) 99(2): 26–9

Kaufman H (2016) A new approach in oxygen wound therapy: an overview of Natrox experience in Israel. Abstract & presentation at World Union of Wound Healing Societies, Florence, Italy 2016.

Khor SN, Lei J, Kam JW, et al (2018) ClariVein™ - One year results of mechano-chemical ablation for varicose veins in a multi-ethnic Asian population from Singapore. *Phlebology* 1:268355518771225

Mani R (2010) Topical oxygen therapy for chronic wounds: a report on the potential of NATROX™ a new device for delivering enriched oxygen to chronic wounds. *J Wound Technol* 9(1): 28–30

Margolis DJ, Gupta J, Hoffstad O et al (2013) Lack of effectiveness of hyperbaric oxygen therapy for the treatment of diabetic foot ulcer and the prevention of amputation: a cohort study. *Diabetes Care* 36(7):1961–6

Mussini E, Hutton JJ Jr, Udenfriend S (1967) Collagen proline hydroxylase in wound healing, granuloma formation, scurvy, and growth. *Science* 157(3791): 927–9

Sen CK (2009) Wound healing essentials: let there be oxygen. *Wound Repair Regen* 17(1):1–18

Wounds UK Expert Panel (2017) *Consensus Round Table Meeting: Clinical Pathway for Using Topical Oxygen Therapy in Practice*. Available at: <https://bit.ly/2Ome6JB> (accessed 11.07.2018)

Yip WL (2015) Influence of oxygen on wound healing. *Int Wound J* 12(6): 620–4

Yu J, Lu S, McLaren AM et al (2016) Topical oxygen therapy results in complete wound healing in diabetic foot ulcers. *Wound Repair Regen* 24(6):1066–72

rate of decrease in wound area is statistically significant, the small number of patients, lack of a placebo control, short study period and other factors require that a much larger study is needed to draw any definitive conclusions. The initial increases in wound size shown by some responding wounds (over up to 6 weeks in this study) indicate that a longer treatment period is required for a definitive study. The significant costs of treatment of patients with DFU and the impact of amputations on quality of life and life expectancy suggest that Natrox® treatment is likely to be cost-effective, a conclusion that was evident from the brief independent health economics study linked to the project. However, input efficacy data for definitive economic modelling requires a larger, more appropriately-designed study.

Yu et al (2016) performed a small randomised controlled trial (RCT) of Natrox® ( $n=10$ ) versus non-placebo control ( $n=10$ ) in DFU patients. Mean duration of DFU prior to enrolment into the study was 76 weeks. Standard of care for both groups included offloading. After 2 months of treatment, 90% of wounds treated in the Natrox® group healed compared to only 30% in the control group.

Kaufman (2016) reported her experience in Israel using the Natrox® device on wounds of varied aetiology including venous leg ulcers (VLU), DFUs, traumatic wounds and pressure ulcers. She found in her cohort of patients that the therapy was very well tolerated and with a mean treatment duration of 36 days, there was a 56% reduction in wound area, more so with VLU than DFU.

Curran and Hayes (2016) documented how the new therapy had changed five patients' quality of life, who had lived with chronic ulcers due to critical limb ischaemia for a total duration of more than 25 years. All ulcers had healed during the treatment with Natrox® and average time to achieve full closure was 22.4 weeks. Patients expressed high satisfaction levels with the device and from a health economic viewpoint total cost of treatment with the device for the five patients was less than a twelfth compared with the total cost of previous standard dressing care (Curran and Hayes, 2016).

An observational study using the new technology in patients with VLU ( $n=10$ ) showed a wound area reduction by a mean of 58.9% over the 6-week study period, with no adverse events and pain scores decreased in all patients (Mani, 2010).

However, all the above-mentioned studies were using Caucasian patient cohorts. The blood vessels in Asians are generally smaller and the

microcirculation more diseased than in our Caucasian counterparts because of the higher incidence of diabetes. Furthermore, patients with chronic venous insufficiency generally present later with poor skin quality and larger leg ulcer wounds in general (Khor et al, 2018). This technology could be beneficial for such patients and improve our limb salvage rates. After revascularization and control of infection, there is little alternative if the wound does not heal apart from further wound debridement or major amputation. A new small randomized controlled trial looking at Natrox® study is currently underway at Singapore General Hospital, Singapore to investigate how this device performs in recalcitrant DFU in Asian patients. This study may show us which DFU or wounds are likely to respond to topical oxygen and what effect it has on the patient *per se* in terms of pain relief and improvement of quality of life. It has very definite potential to improve the healthcare of our diabetic patients.

We present two case studies with severe wounds to illustrate good results in post-surgical diabetic foot wounds from two centres in Asia [Figure 3 and 4], showing proof of concept of the therapy in different geographical locations.

An expert working group has previously agreed that the science behind topical oxygen therapy is persuasive and that clinical evidence and experience to date show that Natrox® has a role in managing DFUs and VLUs with early studies showing an improvement in wound healing times (Wounds UK Expert Panel, 2017). However, there are numerous unanswered questions regarding its potential role and some of the basic science behind its use. These include whether we should potentially use the device prior to lower limb revascularization in DFU in the hope that wound oxygenation may improve sufficiently to avoid angioplasty altogether or at least start the wound healing process before improving the blood supply to the foot. Some of the basic science questions that need to be elucidated include the depth of penetration that oxygen using this device can penetrate in both healthy and infected wounds with heavy biofilm, the optimum flow rate of oxygen to maximise wound healing and the optimum pH that oxygen delivery would work best at in these wounds. WAS

## References

- Castilla DM, Liu ZJ, Velazquez OC (2012) Oxygen: Implications for Wound Healing. *Adv Wound Care (New Rochelle)* 1(6): 225–30
- Curran G, Hayes PD (2016) 27-years of non-healing wounds — 5 patients' lives transformed by topical oxygen therapy. Poster presentation at Wounds UK Conference, Harrogate, UK 2016