

## Clinical effect of subcutaneous application of Cellmax® on treating chronic wounds: a case series



**Authors:**

Harikrishna KR Nair,  
Azizi Ayob, Faris Hazim

Chronic wounds include, but are not limited to diabetic foot ulcers (DFU), venous leg ulcers (VLU), and pressure ulcers (PU) that do not progress through the healing process in a timely manner. This case series aims to investigate the recovery of chronic wounds treated with Cellmax®, which contains secretory factors, bioactives and bioproteins from mesenchymal stem cell (MSC) secretome, based on a standard debridement procedure for wound healing and application of subcutaneous injection of Cellmax as first-line therapy. Seven patients with different underlying comorbidities consented to participate in the case study for varying treatment duration at the Wound Care Unit, Department of Internal Medicine, Hospital Kuala Lumpur, Malaysia. The inclusion criteria include patients with chronic wounds classified as Class 2 and Class 3 as according to Harikrishna Periwound skin classification (HSPC). One patient out of seven patients, saw no reduction in wound size, whereas all other had reduced the wound size and the formation of granulation tissues were observed in all patients over time from week 1 to week 6 after therapy. Cellmax® was also found to be highly tolerable and good safety profile among these seven chronic wound patients.

**Key words:**

- Cellmax
- Chronic wounds
- Secretome
- Stem cells
- Wound healing

**Harikrishna KR Nair**, Professor and Head of the Wound Care Unit, Department of Internal Medicine, Hospital Kuala Lumpur Malaysia;  
**Azizi Ayob**, Biotechnology Incubation Centre, MRANTI Park, Bukit Jalil Kuala Lumpur, Malaysia; **Faris Hazim**, Assistant Medical Officer, Wound Care Unit, Dept of Internal Medicine, Hospital Kuala Lumpur, Malaysia.

Chronic non-healing wounds are those that fail to progress according to the normal phase of the healing process in an orderly or timely fashion. They can be classified into diabetic foot ulcers (DFU), pressure ulcers (PU), venous leg ulcers (VLU) and arterial ulcers (Nunan et al, 2014). There are various common clinical features shared by each of these wounds including prolonged or excessive inflammation, persistent infections, formation of drug-resistant microbial biofilms, and the inability of dermal and/or epidermal cells to respond to reparative stimuli (Attingeret al, 2006; Woo et al, 2007; Stojadinovic et al, 2008). The wound healing can be affected by various factors including the patient's age, comorbidities, health condition, and medications as well as the condition of the wound itself including wound size, location, oxygenation level and the presence of infection (Kee et al, 2019).

Chronic wounds impact heavily on those affected in terms of quality of life and can lead to

limb amputations, and even death. The burden potentiates with the rising numbers of lifestyle diseases, with diabetes taking the lead. Statistics from the National Health and Morbidity Survey 2019 in Malaysia shows that the prevalence of high blood sugar elevated significantly from 11.2% in 2011 to 18.3% in 2019, and only half of them are diagnosed diabetes (National Health and Morbidity Survey, 2013). There is an expected growth in the number of DFUs as a complication of uncontrolled blood sugar, posing a significant challenge to the healthcare system and economic burden throughout the nation. A systematic review reveals that the management of DFU per patient in Malaysia is costing around MYR 6,000 in public setting and about 23% higher in private setting, averaging to MYR 8500 per patient annually (Nair et al, 2022).

In recent years, mesenchymal stem cell (MSC) and its secretome have been shown to play an important role in wound healing (Ennis and Bartholomew, 2013). This MSC

**Table 1. The 2015 Harikrishna Periwound Skin Classification (HPSC) (Nair, 2018)**

Class	Subtype	Periwound condition
0		Normal
1		Fibrous tissue/tissue at risk
2	A	Exudate centered with desiccation
	B	Exudate centered with maceration
	C	Exudate centered with allergy
3		Inflammation without infection
4		Inflammation with infection
5		Atypical (senescent cells/cancer/subcutaneous emphysema)

secretome includes secretory factors, bioactives and bioproteins in the form of protein-based growth factors, cytokines, chemokines and extracellular matrix that could be extracted from MSC and produce stable ingredients that affect wound healing (Wu et al, 2016; Xu et al, 2017). Molecules and secretory factors released by the MSC secretome can promote re-epithelialisation and angiogenesis while inhibiting fibrosis and microbial invasion, all of which aid wound healing. Thus, patients with a chronic wound may require a direct delivery of bioactives and bioproteins-derived functional MSCs via subcutaneous application into the affected area and this could achieve wound healing.

### Objective

This study aims to establish the clinical benefits of new subcutaneous product, Cellmax®, which contains secretory factors, bioactives, and bioproteins of MSC secretome, on chronic wounds.

### Methodology

Patients with hard-to-heal wounds on their lower extremities were selected via randomised sampling in Wound Care Unit, Hospital Kuala Lumpur and they were observed for a period of

4 to 6 weeks. The patients walked-in to the clinic from Monday to Friday (8am-4pm) and were enrolled in this study based on the following.

#### Inclusion criteria:

- DFU, VLU, postoperative wound or trauma wound based on the Harikrishna Periwound Skin Classification (HPSC) classification (Table 1) Nair et al, 2020
- Any wound surface area
- Wound age of at least 4 weeks duration
- Able to comply to at least weekly visit to hospital.

#### Exclusion criteria:

- Ischaemic wounds before effective revascularisation
- Neoplastic wounds
- Underlying abscesses or fasciitis which require incision and drainage
- Underlying osteomyelitis.

All previous dressings were removed from the wounds and any remaining medications were rinsed using sterile water. The necrotic material or slough were removed by standard debridement procedure. The wound beds were dried eventually. For patients that had lower pain tolerance, a local anaesthetic, lidocaine

**Table 2. Wound size and subcutaneous injection technique**

Wound size area measurement (square/cuboid)	Amount of Cellmax	Number of injection (SC injection session)
5cm x 5cm (or 25cm <sup>2</sup> )	1 vial mix with 2ml Sodium Chloride (Amount 2ml)	6–8 SC injection site Approx 0.25ml per injection
7.5cm x 7.5cm (or 56cm <sup>2</sup> )	2 vials mix with 2ml Sodium Chloride (Amount 4ml)	10–12 SC injection site Approx 0.25ml per injection
10cm x 10cm (or 100cm <sup>2</sup> )	3 vials mix with 2ml Sodium Chloride (Amount 6ml)	14–16 SC injection site Approx 0.25ml per injection
More than 10cm x 10cm (or 100cm <sup>2</sup> )	4 vials mix with 2ml Sodium Chloride (Amount more than 8ml)	16–20 SC injection site Approx 0.25ml per injection* (To assess by the Dr)

Note: \*Recommended dose and number of injection of Cellmax®

**Table 2. Demographics of patients and wound condition**

Patient	Gender	Age (year)	Type of wound	Duration of wound	Duration of treatment with Cellmax	Wound bed area at baseline (cm <sup>2</sup> )
1	Female	73	VLU	1 year	7 days	110.5
2	Male	62	DFU	2 years	42 days	30.0
3	Male	60	Trauma	7 years	42 days	126.0
4	Male	63	VLU	11 months	35 days	17.0
5	Male	64	DFU	4 years	21 days	41.5
6	Male	83	DFU	1 month	7 days	7.0
7	Male	73	DFU	2 years	7 days	43.0

Note: Diabetic foot ulcers (DFU) and venous leg ulcers (VLU).

gel 5%, was applied for 10–15 minutes and wiped off.

**Preparation method**

Freeze dried Cellmax in 2ml vial was reconstituted with 2ml sodium chloride solution for a standard dose for all patients. Cellmax was highly dissolved with no sediment noted. Cellmax was applied by subcutaneous (SC) injection into the wound edge, carried out by a medical personnel in the clinic. This SC injection refers to the application of a short needle injection into the tissue layer between the skin and muscle. The SC injection was applied at different periwound points within 1.0 to 3.0mm deep into wound edge and wound base/floor. The number of SC injection is based on wound area as stated in *Table 2*. The SC injection site was approximately 0.5cm-1.0cm between each injection and it follows surrounding the wound edge. The final amount of Cellmax® used was based on the wound size area.

**Wound assessment procedure**

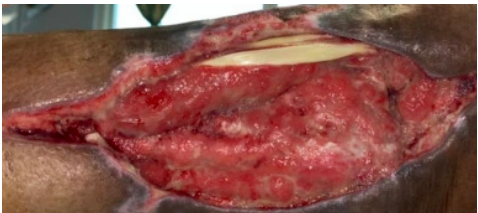

During follow-up visits, all patients were assessed as follows:

- The wound bed was rubbed with sterile gauze and any detachable materials were fully removed
- The length and width of wound bed were measured by using a standardised scale unit. The measurement of wound size/ lesions (length x depth) and their healing progress were assessed every time after the dressing was changed
- The wound bed and periwound were also assessed on its general condition, and any side effects were analysed weekly until the point of granulation starts
- Once the physical assessment was completed, the primary and secondary wound dressing were applied as a standard wound care procedure.

**Case 1. Venous leg ulcer**

Case History:

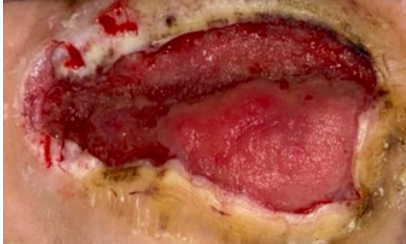
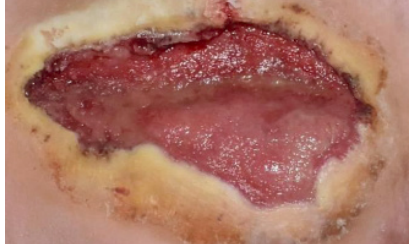
- A 73-year-old female with underlying hypertension, ischaemic heart disease, and Parkinson's disease
- Diagnosis: right venous leg ulcer
- Medications: amlodipine, perindopril, levodopa, benzhexol, aspirin.

Before treatment	After 1 week of treatment
	
<p>Wound Size: 110.5cm<sup>2</sup>                      Wound bed pale red Normal granulation                      Creamy yellow tendon</p>	<p>Wound Size: 110.5cm<sup>2</sup>                      Wound bed bright red                      Normal granulation</p>

## Patient 2. Postoperative on diabetic Charcot foot

### Case History:

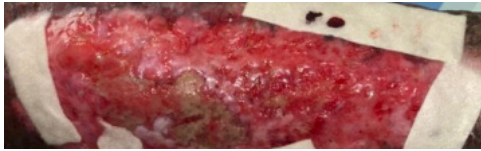

- A 62-year-old male, with underlying diabetes, hypertension, ischaemic heart disease, dyslipidaemia and chronic kidney disease
- Diagnosis: postoperative on diabetic Charcot foot
- Medications: aspirin, metformin, perindopril, metoprolol, atrovastin, vit b complex and insugen.

Before treatment	After 6 weeks of treatment
	
Wound Size: 30.0cm <sup>2</sup> Wound bed pale red 50% maceration	Wound Size: 26.4cm <sup>2</sup> Wound bed pale red 0% maceration

## Case 3. Trauma wound

### Case History:


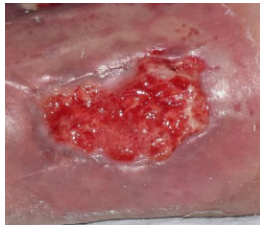
- A 60-year-old male, with underlying diabetes, hypertension, ischaemic heart disease and dyslipidaemia
- Diagnosis: trauma wound
- Medications: aspirin, valsartan, bisoprolol, simvastatin, sitagliptin/metformin, gliclazide modified release, esomeprazole, ferrous fumarate, folic acid, ascorbic acid.

Before treatment	After 6 weeks of treatment
	
Wound Size: 126.0cm <sup>2</sup> Wound bed bright red Normal granulation Little epithelization 40% stubborn slough	Wound Size: 104.5cm <sup>2</sup> Wound bed bright red Normal granulation 20% epithelization 40% stubborn slough

## Case 4. Left venous leg ulcer

### Case History:



- A 63-year-old male with underlying: diabetes, hypertension and dyslipidaemia
- Diagnosis: left leg venous ulcer.

Before treatment	After 3 weeks of treatment
	
Wound Size: 17.0cm <sup>2</sup> Wound bed mainly covered with 98% slough Little to no granulation	Wound Size: 12.1cm <sup>2</sup> Wound bed bright red 50% granulation 10% slough

### Case 5 Chronic venous leg ulcer

Case History:



- A 64-year-old male, with underlying diabetes
- Diagnosis: chronic venous ulcer

Before treatment	After 2 weeks of treatment
	
Wound Size: 41.5cm <sup>2</sup> Wound bed pale red Little to no granulation	Wound Size: 38.6cm <sup>2</sup> Wound bed bright red 50% granulation

### Case 6. Diabetic foot ulcer

Case History:

- A 83-year-old male with underlying disease: diabetes, hypertension and heart disease
- Diagnosis: diabetic wound (right foot)

Before treatment	After 1 week of treatment
	
Wound Size: 7.0cm <sup>2</sup> Wound bed pale red covered with slough	Wound Size: 4.6cm <sup>2</sup> Wound bed bright red No slough Granulation noted

#### Ethics approval and consent to participate

The case series were carried out as per the Declaration of Helsinki's guidelines and approved by the hospital review board. The objective of the study was explained to study participants. Patients gave consent to participate in this study and use clinical images, and case details for publication/research purposes before the start of the study. All study data were collected by the investigators and the case record forms were kept at the Wound Care Unit, Department of Internal Medicine, Hospital Kuala Lumpur, Malaysia. All investigators involved were certified based on the Malaysian Good Clinical Practice (GCP), and the study implementation and data management were in accordance with the Malaysian Good Clinical Practice.

#### Results

We recruited 7 patients in this observational study, with diabetic foot ulcers (n=4), venous leg ulcers (n=2), and postoperative leg ulcer (n=1). **Table 2** shows the demographics of the patients and their wound conditions before therapy or at baseline. There is one female and six males age ranged 60–83 years old (median age: 68 years). The wound duration is from 1 month to 7 years.

The case history of all seven patients which include summary of underlying diseases, diagnosis, medications and their wound conditions during follow-up and while on therapy are shown in **Case 1–7**.

#### Discussion



Several studies on stem cell-derived secretory factors or also known as the MSC-secretome



## Case 6. Diabetic foot ulcer

### Case History:

- A 73-year-old male, with underlying diabetes, hypertension, heart disease, dyslipidemia and chronic limb ischaemia
- Diagnosis: diabetic wound
- Medications: vastarel XR, coplavix 75/100, amiodarone, frusemide, nebivolol, spironolactone, imdur, entresto, glucophage xr, trajenta, jardiance, enerzair

Before treatment	After 1 week of treatment
	
<p>Wound size: 43.0cm<sup>2</sup>                      Wound bed red                      Normal granulation                      Little slough</p>	<p>Wound size: 41.0cm<sup>2</sup>                      Wound bed bright red                      More granulation tissue</p>

without stem cells can promote tissue repair when in different conditions (Pawitan et al, 2014). The secretomes contain cell-secreted factors that could be used for regenerative treatment, which include wound healing and it is relatively safe to the human body. However, MSC-secretome can regulate the inflammatory response, stimulate angiogenesis, remodelling of the extracellular matrix, suppress apoptosis, mediate chemoattraction, and affect fibrosis (Deffune et al, 2020).

A study reported by Chen et al (2021) demonstrated that the use of the secretomes to treat wounds in *in vivo* assays significantly accelerated wound closure and improved regeneration outcome. The study demonstrated that wounds of all groups were almost closed after 15 days, and the secretomes had a significant effect on promoting normal skin regeneration, inhibiting fibrosis and enhancing restoration of the appearance of damaged skin *in vivo* (Chen et al, 2021). A recent clinical study has demonstrated the wound healing process of a 17-year-old male treated with Wharton's Jelly-derived MSC-cellular matrix topical gel improved significantly and the lesion had reduced in size (Chandra et al, 2022).

In our study, it was observed only one patient (*Case 1*) out of seven, saw no reduction in wound size, whereas all other had reduced the wound significantly over time from week 1 to week 6 of therapy. Despite no changes on wound size for *Case 1*, the wound bed was found to be bright red and normal granulation tissues were noted after 7 days. As the duration and frequency of treatment for the patients recruited differed

significantly, and results varied substantially. However, the improvement pattern for all cases indicates that the wound healing rate picks up significantly after more than 7 days of treatment with Cellmax.

We treated four diabetic foot ulcers with multiple comorbidities with Cellmax for between 7 to 42 days, and all of them had a significant reduction in wound size. Their wound beds became bright red, with less slough and more granulation tissue. It was also noted that the previously sloughy tissues had become viable, and the exudate had dried up. Normally, skin wound healing will take around 2 weeks dependent on the wound severity and it will also be affected by existing comorbidities (Szpadarska et al, 2003; Kim et al, 2020). Likewise in our present study, the DFUs age were from 1 month to 2 years. This indicates the severity of the chronic wound condition and complication of poorly controlled blood sugar among the patients. The thwarted wound healing might be related to poor offloading for DFUs and compression therapy for VLU (Kavitha et al, 2014; Raffetto et al, 2020).

From clinical observation, there is no dermatitis, periwound abrasion, skin infection, skin reaction and localised pain following the subcutaneous injection of Cellmax, thus indicating good safety profile and suitability of MSC secretome used in the Cellmax formulation for the human body. Since the MSC secretomes only consists of cell secreted proteins and bioactives, the used of Cellmax for treatment has a very low risk of side effect, and unlikely

to have graft versus host disease, and free from infectious disease. Having periwound tissue intact would speed up the wound healing process and leave the patient generally more comfortable during the recovery period. The improvement demonstrated in wound size, excretion of exudate and formation of granulation tissues reflected on patients with different underlying comorbidities, suggesting Cellmax works for patients with varying aetiologies.

### Limitations

Limitations for this study include the lack of monitoring over nutrition intake, blood sugar control, length of the treatment period, disease status, and chronic wounds classified as Class 4 and 5 as according to HSPC were not included as more aggressive treatment would be required for such wounds. More patients with a standard follow-up period and therapy regime should be conducted to further access the case studies.

### Conclusion

This case series demonstrated preliminary clinical efficacy of Cellmax containing secretory factors, bioactives and bioproteins in treating chronic wounds by promoting wound closure and improved regeneration outcome. Significant wound size reduction, exudates drying, and formation of granulation tissues indicate that Cellmax works for patients with DFUs, venous and arterial lower limbs ulcers. The highly selective action on wound tissue and simple application of this SC injection shows its potential to be a valuable insert for local wound care management in the healthcare setting and outpatient treatment. Cellmax was also found to be tolerable and had a good safety profile among seven chronic wound patients. WAS

### Declaration of interest

Dedikasi ABA Biosciences supplied the Cellmax® used for this study. However, the authors have no conflicts of interest to declare.

### References

Attinger CE, Janis JE, Steinberg J et al (2006) Clinical approach to wounds: debridement and wound bed preparation including the use of dressings and wound-healing adjuvants. *Plast Reconstr Surg* 117:725–1095. <https://doi.org/10.1097/01.prs.0000225470.42514.8f>

Chandra CC, Pratiwi YI and Tan ST (2022) Potential application of Wharton's jelly-derived mesenchymal stem cells conditioned medium (WJMSCs-CM) on delayed wound healing: a case report. *J Pharm Res Int* 2022; 34:1–6. <https://doi.org/10.9734/jpri/2022/v34i4A35393>

Chen L, Cheng L, Wangg Z, et al. Conditioned medium-electrospun fiber biomaterials for skin regeneration.

*Bioact Mater* 2021; 6:361–374.

Deffune E, Prudenciatti A, Moroz A (2020) Mesenchymal stem cell (MSC) secretome: a possible therapeutic strategy for intensive-care COVID-19 patients. *Med Hypotheses* 142:109769. <https://doi.org/10.1016%2Fj.mehy.2020.109769>

Ennis WJ, Sui A, Bartholomew A (2013) Stem cells and healing: impact on inflammation. *Adv Wound Care (New Rochelle)* 2(7):369–378. <https://doi.org/10.1089%2Fwound.2013.0449>

Kavitha KV, Tiwari S, Purandare VB et al (2014) Choice of wound care in diabetic foot ulcer: A practical approach. *World J Diabetes* 5(4):546–56. <https://doi.org/10.4239%2Fwjcd.v5.i4.546>

Kee KK, Nair HKR, Yuen NP (2019) Risk factor analysis on the healing time and infection rate of diabetic foot ulcers in a referral wound care clinic. *Journal of Wound Care* 28(Sup1): S4–13. <https://doi.org/10.12968/jowc.2019.28.sup1.s4>

Kim HS, Chen J, Wu LP et al (2020) Prevention of excessive scar formation using nanofibrous meshes made of biodegradable elastomer poly(3-hydroxybutyrate-co-3-hydroxyvalerate). *J Tissue Eng* 11: 2041731420949332. <https://doi.org/10.1177/2041731420949332>

Nair HKR, Chong SS, Othman AM (2020) Validation of Harikrishna Periwound Skin Classification for wound assessment. *J Wound Care* 29(Sup4):S44–8. <https://doi.org/10.12968/jowc.2020.29.sup4.s44>

Nair HKR, Norlizah P, Mariam MNet al (2022) Diabetic foot ulcer in Malaysia: consensus on treatment patterns, health care utilization and cost. [Online ahead of print]. *Int J Low Extrem Wounds* <https://doi.org/10.1177/15347346221090096>

National Health and Morbidity Survey 2019 Ministry of Health Malaysia. <https://tinyurl.com/yc88dy62> (accessed 10 October 2022)

Nunan R, Harding KG, Martin P (2014) Clinical challenges of chronic wounds: searching for an optimal animal model to recapitulate their complexity. *Dis Model Mech* 7(11):1205–13. <https://doi.org/10.1242/dmm.016782>

Pawitan JA (2014) Prospect of stem cell conditioned medium in regenerative medicine. *Biomed Res Int* 2014:965849. <https://doi.org/10.1155/2014/965849>

Raffetto JD, Ligi D, Maniscalco R et al (2020) Why venous leg ulcers have difficulty healing: overview on pathophysiology, clinical consequences, and treatment. *J Clin Med* 10(1):29. <https://doi.org/10.3390/jcm10010029>

Stojadinovic A, Carlson JW, Schultz GS et al (2008) Topical advances in wound care. *Gynecol Oncol* 111(2 Suppl):S70–S80. (2 Suppl)

Szpadarska AM, Egozi EI, Gamelli RL et al (2003) The effect of thrombocytopenia on dermal wound healing. *J Invest Dermatol* 120(6):1130–7. <https://doi.org/10.1046/j.1523-1747.2003.12253.x>

Woo K, Ayello EA, Sibbald RG (2007) The edge effect: current therapeutic options to advance the wound edge. *Adv Skin Wound Care* 20:99–117. <https://doi.org/10.1097/00129334-200702000-00009>

Wu J, Zhu J, He C et al (2016) Comparative study of heparinpoloxamer hydrogel modified bFGF and aFGF for in vivo wound healing efficiency. *ACS Appl Mater Interfaces*. 8(29):18710–21. <https://doi.org/10.1021/acsami.6b06047>

Xu H-L, Chen PP, ZhuGe DL et al (2017) Liposomes with silk fibroin hydrogel core to stabilize bFGF and promote the wound healing of mice with deep second-degree scald. *Adv Healthc Mater* 6(19). <https://doi.org/10.1002/adhm.201700344>