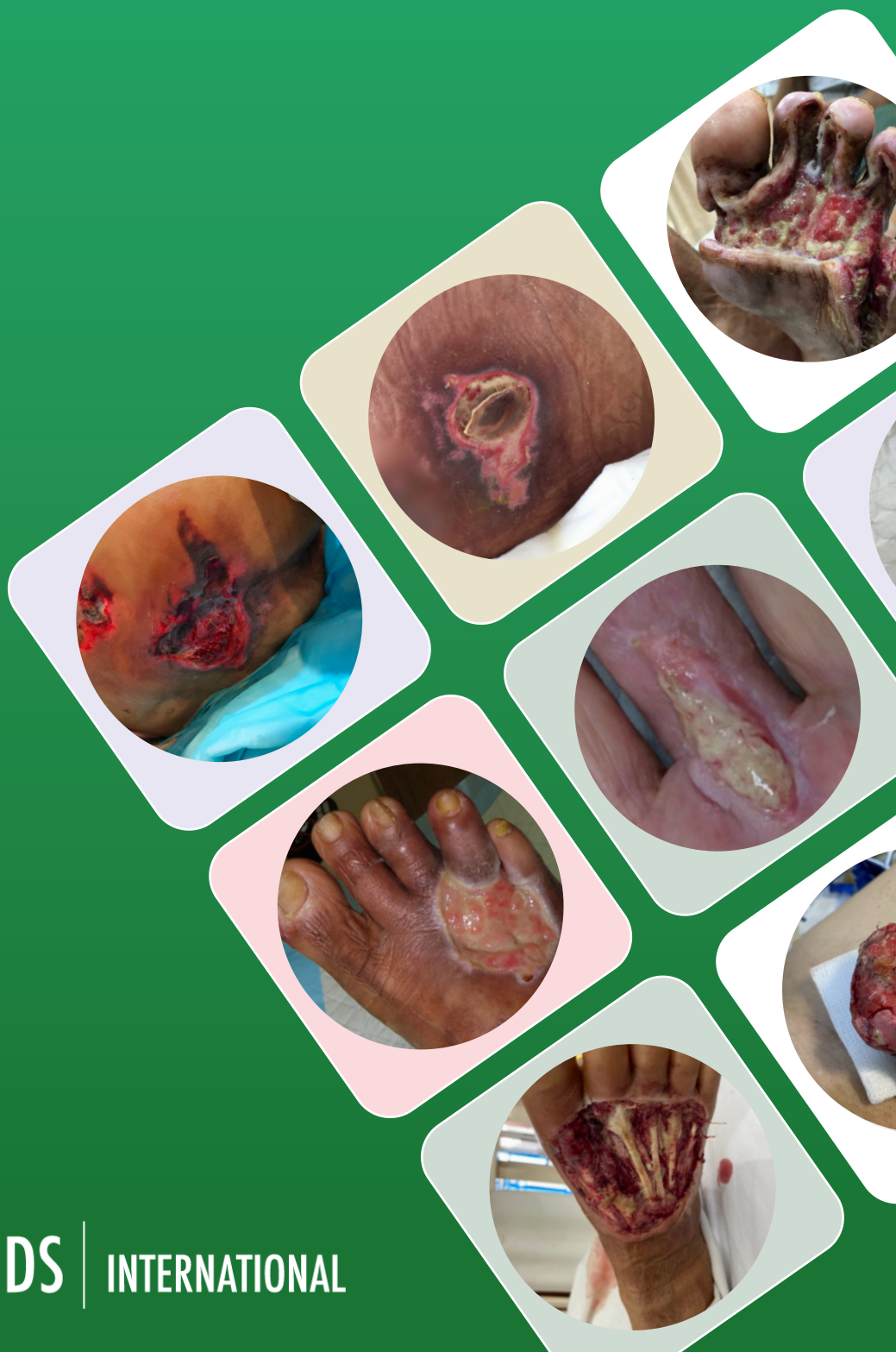

INTERNATIONAL **CASE STUDIES**

Retrospective case series: Application of the M.O.I.S.T. concept to the healing of chronic wounds

CASE STUDY SERIES 2024



WOUNDS | INTERNATIONAL

Published by

Wounds International
A division of Omniamed Communications Ltd
108 Cannon Street
London EC4N 6EU, UK
Tel: +44 (0)20 3735 8244

Email: info@omniamed.com
www.woundsinternational.com

WOUNDS | **INTERNATIONAL**

© Wounds International, 2024

Suggested citation

Wounds International (2024) *Retrospective case series: Application of the M.O.I.S.T. concept to the healing of chronic wounds*. Wounds International, London, UK

Free download available from:
www.woundsinternational.com

All rights reserved ©2024. No reproduction, copy or transmission of this publication may be made without written permission.

No paragraph of this publication may be reproduced, copied or transmitted save with written permission or in accordance with the provisions of the Copyright, Designs and Patents Act 1988 or under the terms of any license permitting limited copying issued by the Copyright Licensing Agency, 90 Tottenham Court Road, London, W1P 0LP.



Supported by an educational grant from Mölnlycke.

The views expressed in this publication are those of the authors and do not necessarily reflect those of Mölnlycke.

Introduction

M.O.I.S.T. (Moisture balance, Oxygen balance, Infection control, Supporting strategies and Tissue management) is an educational model that has been created to support healthcare practitioners in the systematic planning and delivery of topical treatment of chronic wounds. It extends beyond the principles of T.I.M.E. (Tissue management, Infection control, Moisture balance and Epithelial (or Edge) advancement; Schultz et al, 2003; 2004) by incorporating Oxygen balance and Supporting strategies. The concept was developed in 2017 by the WundD.A.CH expert group, an umbrella group for German-speaking organisations in the field of chronic wound management (Dissemond et al, 2022; [Box 1](#)).

How does the M.O.I.S.T. concept work?

The M.O.I.S.T. concept has been created as a reference tool to guide and support healthcare practitioners in identifying suitable management goals and treatment options for patients presenting with a chronic wound in clinical practice. To facilitate the appropriate application of the M.O.I.S.T. concept, it is encouraged that clinicians conduct a systematic and holistic wound assessment using tools like HEIDI (History, Examination, Investigation, Diagnosis and Implementation; Harding et al, 2007; Dissemond et al, 2022). Following a systematic and holistic assessment of the patient to diagnose the aetiology of the wound and identify patient-related factors impacting the wound, practitioners can use the M.O.I.S.T. acronym to identify suitable management goals and treatment options. The elements of M.O.I.S.T. are not intended to be reviewed in a specific order; instead, the elements should be considered in the order determined by the healthcare practitioner to be the most appropriate.

Each letter within the M.O.I.S.T. concept relates to an aspect of local chronic wound management [[Box 1](#)]:

Box 1. The M.O.I.S.T. concept in local chronic wound management	
Moisture balance	Exudate is essential for wound healing; moisture imbalance can delay or inhibit healing (World Union of Wound Healing Societies [WUWHS], 2019). Excess exudate should be absorbed and locked away from the wound bed while dry wounds need to be moistened
Oxygen balance	Oxygen supports metabolic processes; hypoxia contributes to wound chronicity (Schreml et al, 2010). Improving wound bed oxygenation supports all phases of healing. Patients should be offered surgical revascularisation if they have arterial disease and are fit for surgery. If this is insufficient, topical oxygen therapy can be used to treat local hypoxia (Gottrup et al, 2017)
Infection control	Chronic wounds are at high risk of infection, which is associated with pain, oedema, malodour, delayed healing and - if not addressed promptly - hospitalisation, risk of amputation or death. Infection control measures aim to address signs and symptoms of local and systemic infection, reduce bioburden at the wound bed and prevent biofilm formation. Topical antimicrobial solutions and antimicrobial dressings that attack or bind microbes and antiseptics should be selected in line with antimicrobial stewardship principles and local/national protocols and guidelines. Debridement of the wound bed, regular cleansing and antimicrobial dressings should be used to reduce bioburden (WUWHS, 2016)
Supporting strategies	If the wound environment is unbalanced, healing may not progress as expected and supporting strategies, such as local advanced therapeutic treatments that act on matrix metalloproteinases, growth factors or proinflammatory mediators, may prove beneficial (Dissemond et al, 2022)
Tissue management	Cleansing and debridement prepare the wound bed and support tissue management. Wound bed preparation as well as granulation and reepithelialisation can be supported by adjuvant therapies, such as negative pressure wound therapy (NPWT).

[Table 1](#) summarises the goals, assessments and evidence-based treatments associated with each of the five factors included within the M.O.I.S.T. concept. The outcome of treatment and the patient's expectations should be discussed and defined at the start of treatment, and they should be reassessed on a regular basis as expectations change. Validated clinical rating tools should be used to track clinical outcomes over time, such as wound size/volume reduction and percentage of tissue types in the wound bed. Additionally, patient-related outcomes, such as treatment satisfaction and pain levels, should be considered and documented.

Local wound care should also be included as part of holistic patient care. If the patient is malnourished, their nutritional needs should be addressed. If poor oxygenation is due to a respiratory disease, low haemoglobin levels or another cause, management of the underlying condition should be reviewed and optimised. Offloading (for diabetic foot ulcers) and compression therapy (for venous leg ulcers) should be implemented when appropriate.

Table 1. Topical wound therapy recommendations in accordance with the M.O.I.S.T. concept (adapted from Dissemond et al, 2022)		
M.O.I.S.T.	Goals and actions	Topical wound therapy options aligned with evidence-based practice
Moisture balance	<p>Goals: Create a balanced moist healing environment</p> <p>Actions: Assess cause, quantity, type, colour, odour and consistency of exudate</p>	<p>Primary dressing based on moisture level:</p> <ul style="list-style-type: none"> • Dry: Hydrogel dressings or semi-permeable films • Low: Hydrogel dressings, semi-permeable films or foams • Moderate: Foams, alginates, fibres or superabsorbent polymer dressings • High: Foams, fibres, superabsorbent polymer dressings or NPWT <p>A secondary dressing may be required for moisture balance in moderately to highly exuding wounds:</p> <ul style="list-style-type: none"> • Viscous exudate consistency: Dressings with large pores or open cells • Non-viscous exudate consistency: Dressings with smaller pores
Oxygen balance	<p>Goals: Improve tissue perfusion and local oxygenation at the wound bed</p> <p>Actions: Assess local and limb oxygenation (e.g. skin temperature, sensation, colour, pulse, condition and pain)</p>	<p>Refer for vascular assessment and/or intervention if arterial disease is suspected.</p> <p>After arterial disease is discounted or addressed, consider using topical oxygen therapy after debridement, which can be administered through various modalities:</p> <ul style="list-style-type: none"> • Continuous delivery of oxygen • Low constant pressure oxygen in a contained chamber • Higher cyclical pressure oxygen • Oxygen released through dressing or gel • Oxygen transfer via haemoglobin • Application of oxygen species <p>If topical oxygen therapy or devices are not available, indirect treatment, such as hyperbaric oxygen therapy, may be considered</p>
Infection control	<p>Goals: Avoid wound infection or treat existing infection</p> <p>Actions: Assess local infection, spreading infection, systemic infection and infection behaviour – acute or chronic</p>	<p>Follow wound hygiene principles, including regular cleansing and debriding</p> <p>Use antimicrobial products according to antimicrobial stewardship principles, local protocol and official national and international guidelines:</p> <ul style="list-style-type: none"> • Antiseptics (e.g. povidone-iodine, chlorhexidine, hydrogen peroxide and sodium hypochlorite) • Topical antimicrobial solutions (e.g. polyhexanide and octenidine) • Antimicrobial dressings (e.g. those containing silver, medical honey, polyhexanide and octenidine) • Non-antimicrobial dressings (e.g. those containing dialkylcarbomoyl chloride)
Supporting strategies	<p>Goals: Create a supportive wound environment to stimulate healing</p> <p>Actions: Assess progression and wound healing assessments (e.g. pressure ulcer scale for healing)</p>	<p>Consider selecting a supporting therapy that might help to modulate the wound bed environment:</p> <ul style="list-style-type: none"> • Control and modulate matrix metalloproteinases • Optimise pH • Protect growth factors • Control proinflammatory mediators • Support topical wound scaffolds (collagen dressings) • Implement local stem cell therapy
Tissue management	<p>Goals: Remove devitalised tissue and debris, to form healthy granulation and epithelial tissue</p> <p>Actions: Assess wound bed visually and objectively; use wound assessment tools and/or photographs</p>	<p>Cleanse and debride wound bed. The method and products used should depend on the clinician's competency, the treatment setting and patient acceptance:</p> <ul style="list-style-type: none"> • Cleanse with normal saline (0.9%), Ringer's solution or preserved solution • Debride using autolytic, biological, mechanical, sharp, surgical or enzymatic methods <p>Apply a dressing or device (e.g. NPWT) that supports a wound healing environment</p>

Application in clinical practice

In 2022, a group of practitioners met to discuss how the M.O.I.S.T. concept could be applied in clinical practice and how it could best be implemented and delivered to enhance wound care in the Asia-Pacific region (Dissemond et al, 2022). It was hoped that the M.O.I.S.T. concept could address some gaps and challenges identified in the Asia-Pacific region, including (Dissemond et al, 2022):

- Lack of internationally standardised care
- A focus on local rather than holistic wound care
- Insufficient staff knowledge
- High chronic infection rates
- Limited shared decision-making or care between healthcare practitioners and patients.

Therefore, a treatment algorithm was developed to support the implementation of the M.O.I.S.T. concept in practice [Figure 1]. The M.O.I.S.T. concept and algorithm can be used as a reference by specialist wound care practitioners. It can also aid in educating and guiding nurses, doctors and other allied healthcare professionals in their decision-making processes. It should be referred to throughout the patient's treatment journey, as factors that influence healing may change over time and progression towards healing can stall.

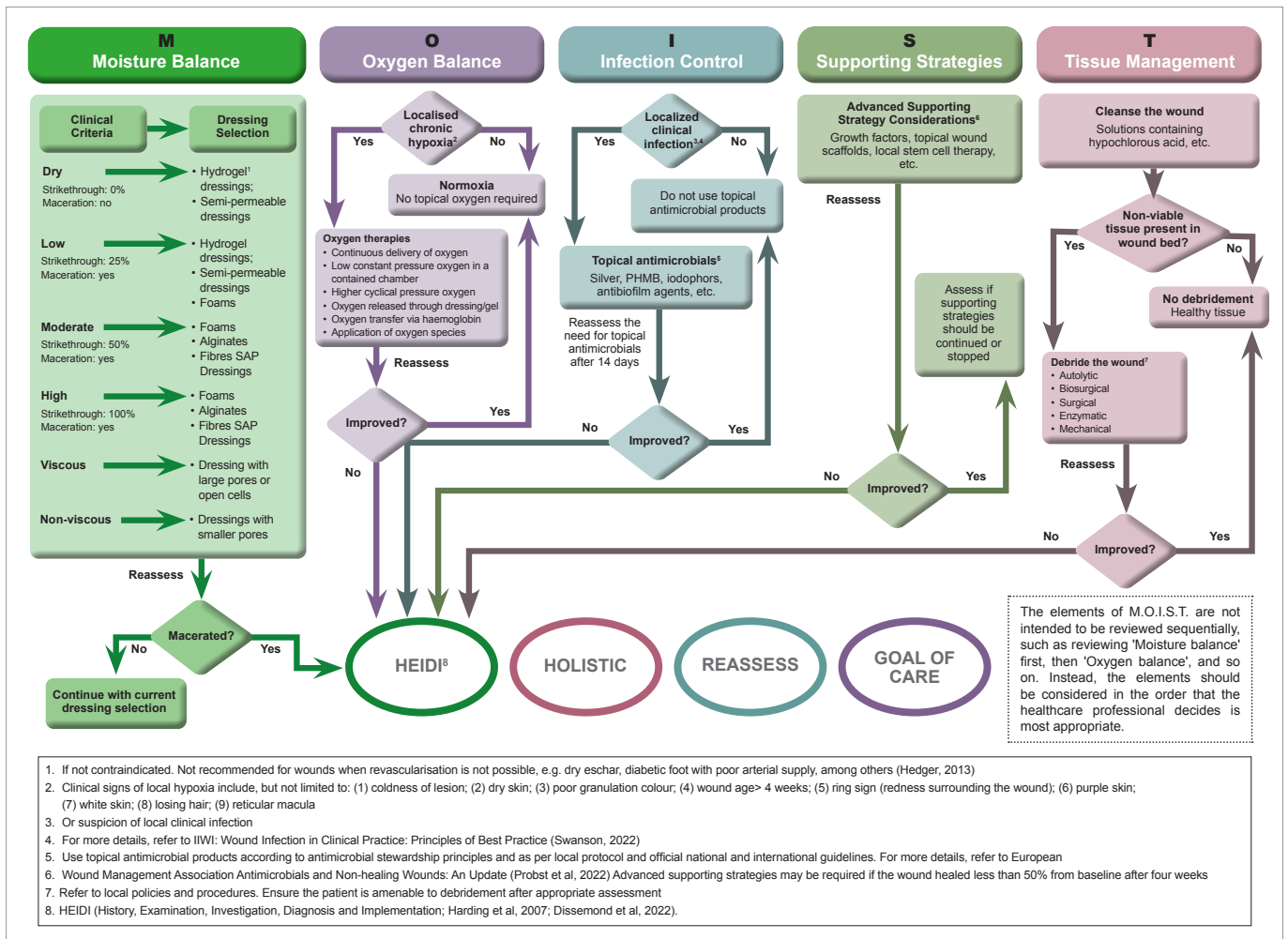


Figure 1. Treatment algorithm in accordance with the M.O.I.S.T. concept (adapted from Dissemmond et al, 2022)

Conclusion

This retrospective case study series provides examples of how the M.O.I.S.T. concept has been successfully applied in the treatment of chronic wounds by Asia-Pacific-based healthcare practitioners. It covers a range of chronic wounds, including foot wounds in people with diabetes, surgical wounds, pressure ulcers and third-degree burns.

Many of the wounds covered in this case study series were infected and a number of patients were at risk of amputation when they initially presented for treatment. However, with the application of the M.O.I.S.T. concept to identify and optimise factors affecting individual wounds, all wounds showed good progress toward healing or achieved complete healing.

REFERENCES

Dissemmond J, Malone M, Ryan H et al (2022) Implementation of the M.O.I.S.T. concept for the local treatment of chronic wounds into clinical practice. Advisory Panel Meeting Report. *Wounds International* 13(4): 34

Probst S, Apelqvist J, Bjarnsholt T et al (2022) Antimicrobials and Non-healing Wounds: An Update. *European Wound Management Association*

Gotttrup F, Dissemmond J, Baines et al (2017) Use oxygen therapies in wound healing, focusing on topical and hyperbaric oxygen treatment. *J Wound Care* 26(Sup 5): S1-S43

Harding K, Gray D, Timmons J, Hurd T (2007) Evolution or revolution? Adapting to complexity in wound management. *Int Wound J* 4(Suppl 2): 1-12

Hedger C (2013) Choosing the appropriate dressing: Hydrogels and sheets. *Wound Essentials* 8: 9-12

Schreml S, Szeimies RM, Prantl L et al (2010) Oxygen in acute and chronic wound healing. *Br J Dermatol* 163(2): 257-68

Schultz GS, Sibbald RG, Falanga V et al (2003) Wound bed preparation: a systematic approach to wound management. *Wound Repair Regen* 11(Suppl 1): S1-28

Schultz GS, Barillo DJ, Mazingo DW et al (2004) Wound bed preparation and a brief history of TIME. *Int Wound J* 1(1): 19-32

World Union of Wound Healing Societies (2016) Management of biofilm. *Wounds International*

Swanson T, Angel D, Sussman G et al (2022) Wound infection in clinical practice: principles of best practice. *Wounds International*

World Union of Wound Healing Societies (2019) Wound exudate: effective assessment and management. *Wounds International*

CASE STUDY 1: DEHISCED SURGICAL WOUND

Author: Doris Hung Ching Pen, Nurse Clinician (Wound Care), National University Polyclinic, Singapore

Patient and wound history

- 60-year-old female
- Medical history: Hypertension, peripheral arterial disease, kidney disease, hyperlipidaemia
- Wound located on flexor middle finger of right hand; present for 54 days; diagnosed with tenosynovitis localised with cellulitis
- Surgical history: Surgical debridement of wound; patient declined further wound debridement treatments and concomitant right upper limb angioplasty for conservative management
- Previous treatment: Inappropriate use of antibacterial ointment under Granulox® (haemoglobin spray), antimicrobial, non-antimicrobial and retention dressings.

Intervention and treatment regimen

- Granudacyn® Wound Irrigation Solution/Gel (intervention), a hypochlorous acid solution/gel, was chosen to cleanse the wound, reduce risk of infection and facilitate autolysis. Granulox® (intervention), a topical haemoglobin spray, was selected for its ability to improve wound bed oxygenation. Mepilex® Border Flex (intervention), a foam dressing, was chosen for its conformability and wound exudate management
- Sharp debridement was performed up to Day 34; during all dressing changes, Granudacyn® Solution was used
- The wound was coated with a thin layer of Granulox® and Granudacyn® Gel (primary dressings), dressed with Mepilex® Border Flex (secondary dressing), and secured using Tubifast® (tubular retention bandage).
- Dressings were changed twice weekly.

Table 2. Wound assessment and local treatment regimen following the principles of M.O.I.S.T.

Wound assessment		Local wound treatment
Moisture balance	Exudate was low, non-viscous and bloody/serosanguinous	Mepilex® Border Flex (self-adherent soft silicone foam dressing)
Oxygen balance	<ul style="list-style-type: none"> ▪ >90% stenosis of the distal radial artery and total occlusion of the distal ulnar artery ▪ Wound duration: approximately 8 weeks ▪ Slow healing response suggestive of hypoxia 	Granulox® (haemoglobin spray)
Infection control	Michon stage II infection	Granudacyn® Wound Irrigation Solution (hypochlorous acid)
Supporting strategies	Wound progression after treatment was initiated	Not required
Tissue management	100% necrotic tissue in wound bed	<ul style="list-style-type: none"> • Granudacyn® Wound Irrigation Solution (hypochlorous acid) for cleansing • Granudacyn® Wound Gel for autolysis • Conservative, sharp debridement when necessary

Wound progression

	Initial study intervention (Day 1)	Day 27	Day 41	Day 51
				
Wound area	5.3cm ²	1.9cm ² (↓64%)	0.3cm ² (↓94%)	Healed
Signs of infection	Yes*	Resolved	-	-
Viable tissue	0%	30%	100%	-
Periwound	Maceration	Healthy	Healthy	Healthy
Exudate	Low, non-viscous, yellow/green	Low, non-viscous, clear/serous	Low non-viscous clear/serous	-
Pain score	2/10**	2/10**	2/10**	0/10

Clinician perspective

"This case highlights the importance of the correct rationale and appropriate use of a dressing product to maximise its healing benefit, and potentially reduce treatment cost and healing time, and improve the patient's quality of life. The M.O.I.S.T. concept has provided me with a framework for planning and decision-making when treating my patient's wound in my daily clinical practice."

*Mild pain, warmth, oedema and exudate, **Pain prior to dressing change, on dressing removal, during wound cleansing and dressing reapplication

CASE STUDY 2: DIABETES-RELATED FOOT ULCER WITH SEVERE INFECTION

Author: Chumpon Wilasrusmee, Professor of General Surgery, Faculty of Medicine, Ramathibodi Hospital, Mahidol University, Thailand

Patient and wound history

- 54-year-old male
- Medical history: Type 2 diabetes (poorly controlled), peripheral arterial disease (ankle-brachial index = 0.6)
- Wound located on left plantar foot; present for one month
- Surgical history: Surgical debridement of infected diabetes-related foot ulcer; amputation of the left fifth toe
- Previous treatment: Normal saline solution and povidone-iodine antiseptic solution; patient refused advice for a left below-knee amputation.





Intervention and treatment regimen

- **Granudacyn® Wound Irrigation Solution** (intervention), a hypochlorous acid solution/gel, was chosen to cleanse the wound to reduce risk of infection. **Granulox®** (intervention), a topical haemoglobin spray, was selected for its ability to improve wound bed oxygenation to support healing
- Wound sites were debrided (bedside limited sharp debridement) and cleansed with Granudacyn® Wound Irrigation Solution
- The wound was coated with a thin layer of Granulox® spray and dressed with silver-containing hydrofibre (primary dressing) and gauze (secondary dressing)
- Dressings were changed every 2-5 days.

Table 3. Wound assessment and local treatment regimen following the principles of M.O.I.S.T.

Wound assessment		Local wound treatment
Moisture balance	Exudate was high, viscous and purulent	Silver-containing hydrofibre
Oxygen balance	<ul style="list-style-type: none"> • Peripheral vascular disease • Wound duration: >4 weeks • Slow healing response suggestive of hypoxia 	Granulox® (haemoglobin spray)
Infection control	Signs of severe infection (increased pain, warmth and exudate; erythema, oedema and malodour)	<ul style="list-style-type: none"> • Granudacyn® Wound Irrigation Solution (hypochlorous acid) • Silver-containing hydrofibre • Antibiotics
Supporting strategies	Wound progression after treatment was initiated	Not required
Tissue management	90% necrotic tissue and 10% sloughy tissue in wound bed	<ul style="list-style-type: none"> • Granudacyn® Wound Irrigation Solution (hypochlorous acid) for cleansing • Granudacyn® Wound Gel (hypochlorous acid) for autolysis • Conservative, sharp debridement when necessary

Wound progression

	Initial study intervention (Day 1)	Day 30	Day 60	3.6 years
				
Wound area	100cm ²	25cm ² (↓75%)	Healed	Regenerated, healthy skin with very little scarring
Wound depth	3cm	1cm (↓67%)	-	
Signs of infection	Yes*	Improved	-	
Viable tissue	0%	85%	-	
Periwound	Eythema and maceration	Improved condition	Healthy	
Exudate	High, viscous, purulent	Low, non-viscous, clear/serous	-	
Pain	3/10**	0/10	0/10	

Clinician perspective

The use of Granudacyn® and Granulox® promoted the successful healing of a diabetes-related foot ulcer, which was at high risk of sepsis and limb amputation. This case highlights the importance of taking a proactive approach to wound management, guided by the principles of M.O.I.S.T.

*Severe pain, warmth, exudate, erythema, oedema and malodour. **Pain experienced prior to dressing change, on dressing removal and during wound cleansing

CASE STUDY 3: EXCISED NON-VIABLE SKIN GRAFT ON THE NEOPHALLUS

Author: Tan Kok Kuan, Medical Director, Dr Tan Medical Center, Novena Medical Centre, Singapore

Patient and wound history

- 46-year-old male
- Medical history: Type 2 diabetes mellitus, hypertension, hyperlipidaemia; receiving testosterone replacement therapy for gender transitioning
- Surgical history: Split-thickness skin graft, performed following neophallus reconstruction as part of gender reassignment surgery
- 14 days post-surgery, the graft was unhealthy with necrosis. Over the following nine days, the graft tissue was monitored until the non-viable portion of the graft was excised from the ventral aspect of the neophallus. Pain management was not a consideration as the neophallus lacked innervation
- Previous treatment: Mepilex® Border Lite, secured with a fixation bandage.

Intervention and treatment regimen

- **Granudacyn® Wound Irrigation Solution** (intervention), a hypochlorous acid solution, was chosen to cleanse the wound and facilitate mechanical debridement with moistened gauze. **Granulox®** (intervention), a topical haemoglobin spray, was selected to improve wound bed oxygenation. **Melgisorb® Ag** (intervention), a silver-containing alginate dressing, was selected for its antimicrobial action and ability to manage exudate. **Mepilex® Border Lite** (intervention), a thin and conformable foam dressing, was chosen for its suitability for difficult-to-dress areas
- Soft mechanical debridement (gauze soaked in Granudacyn®) was performed on Days 3, 6 and 10. Subsequently, debridement was only required to remove hypergranulation tissue on Days 33, 63 and 83
- During all dressing changes, the wound was cleansed using Granudacyn®
- The wound was coated with a thin layer of Granulox®, dressed with Mepilex® Border Lite (primary dressing) and secured with a fixation bandage. Starting from Day 3 and onwards, Melgisorb® Ag was applied before Mepilex® Border Lite. At Day 88, wound dressings were discontinued, but cleansing with Granudacyn® was continued for a further 29 days until the wound had healed
- During the initial three weeks of the study, the median dressing wear time was 3.5 days (range 3–4 days). Over the subsequent 9.5 weeks, median dressing wear time increased to six days (range 4–8 days).

Table 4. Wound assessment and local treatment regimen following the principles of M.O.I.S.T.

Wound assessment		Local wound treatment
Moisture balance	Exudate was low, non-viscous and clear/serous	Mepilex® Border Lite (self-adherent, soft silicone foam dressing)
Oxygen balance	Exposed tissue was pale, unhealthy and sloughy, suggestive of hypoxia	Granulox® (haemoglobin spray)
Infection control	<ul style="list-style-type: none"> ▪ Unhealthy wound bed ▪ Signs of infection at first dressing change (increased exudate and malodour) 	<ul style="list-style-type: none"> ▪ Granudacyn® Wound Irrigation Solution (hypochlorous acid) ▪ Melgisorb® Ag (silver-containing alginate dressing) from first dressing change onwards
Supporting strategies	Wound progression after treatment was initiated	Melgisorb® Ag (silver-containing alginate dressing) from first dressing change onwards
Tissue management	>50% non-viable graft tissue with the presence of necrosis	<ul style="list-style-type: none"> ▪ Granudacyn® Wound Irrigation Solution for cleansing ▪ Mechanical debridement (using gauze soaked in Granudacyn®)

Clinician perspective

The clinician was extremely satisfied with the positive outcome of the treatment regimen. Granudacyn® and Melgisorb® Ag successfully helped to reduce wound bioburden, Granulox® facilitated wound oxygenation, and Mepilex® Border Lite provided excellent exudate management, which, after the removal of a supra-urethra catheter, helped prevent occlusion of the meatus of the neo-urethra, and its water-resistant nature protected the wound from urine.

Initially, the patient had received limited post-operative wound care instructions, and he was understandably worried about the eventual aesthetic and functional outcome. At the end of the study, he was happy and satisfied with the outcome.

According to the clinician: "The M.O.I.S.T. concept helped me break down a seemingly complicated wound into manageable components, allowing me to easily apply sound wound management principles."

Wound progression

	Initial study intervention (Day 1)	Day 6	Day 33
			
Wound area	42.8cm ²	30cm ² (↓30%)	18cm ² (↓58%)
Wound depth	0.5cm	0.5cm	0cm
Signs of infection	No	Mild exudate and malodour	No
Viable tissue	80%	30%	100%
Periwound	80%	Healthy	Mild maceration
Exudate	Low, non-viscous, clear/serous	Moderate, non-viscous, serosanguinous	Low, non-viscous, clear/serous
	Day 49	Day 88	Day 117
			
Wound area	11.3cm ² (↓74%)	2cm ² (↓95%)	Healed
Wound depth	0cm	0cm	-
Signs of infection	No	No	-
Viable tissue	100%	100%	-
Periwound	Healthy	Healthy	Healthy
Exudate	None	None	-

CASE STUDY 4: DIABETES-RELATED FOOT ULCER WITH OSTEOMYELITIS

Author: Doris Hung Ching Pen, Nurse Clinician (Wound Care), National University Polyclinic, Singapore

Patient and wound history

- 63-year-old female
- Medical history: Type 2 diabetes, hypertension, hyperlipidaemia
- Maceration noted between web spaces of the third and fourth toe, which further reduced stability of the fourth toe. Patient declined amputation, preferring conservative management; wound present for eight days
- Surgical history: Surgical debridement performed for circumferential necrosis located on dorsal foot and around base of the fourth toe
- Previous treatment: Tulle gras dressing, Mepilex® (foam dressing) and crepe bandage.





Intervention and treatment regimen

- Granudacyn® Wound Irrigation Solution/Gel (intervention), a hypochlorous acid solution/gel, was chosen to cleanse the wound and reduce risk of infection. Granulox® (intervention), a topical haemoglobin spray, was selected to improve wound bed oxygenation to support healing. Mepilex® XT (intervention), a foam dressing, was chosen for its conformability and wound exudate management
- Sharp debridement was performed up to Day 53, with Granudacyn® Solution used during all dressing changes
- Granudacyn® Gel was applied initially, followed by Mepilex® XT and Tubifast® (tubular retention bandage)
- After Day 12, a thin coat of Granulox® was applied to the wound tissue before the application of Mepilex® XT
- Dressings were changed daily for ten days, then reduced to three times per week, with consistent use of an offloading shoe.

Table 5. Wound assessment and local treatment regimen following the principles of M.O.I.S.T.

Wound assessment		Local wound treatment
Moisture balance	Exudate was moderate, non-viscous and green/yellow	Mepilex® XT (non-bordered soft silicone foam dressing)
Oxygen balance	<ul style="list-style-type: none"> • Wound duration: approximately three weeks • Slow healing response suggestive of hypoxia 	Granulox® (haemoglobin spray; commenced on Day 12)
Infection control	<ul style="list-style-type: none"> • Signs of infection (increased pain, warmth and exudate; oedema) • Suspected presence of biofilm over wound bed 	<ul style="list-style-type: none"> • Granudacyn® Wound Irrigation Solution (hypochlorous acid) • Antibiotics
Supporting strategies	Wound progression after treatment was initiated	Not required
Tissue management	Sloughy biofilm covered 90% of the wound bed	<ul style="list-style-type: none"> • Granudacyn® Wound Irrigation Solution (hypochlorous acid) for cleansing • Granudacyn® Wound Gel for autolysis • Conservative, sharp debridement when necessary

Wound progression

	Initial study intervention (Day 1)	Day 14	Day 46	Day 67
				
Wound area	15.8cm ²	14cm ² (↓11%)	1.4cm ² (↓91%)	Healed
Signs of infection	Yes*	Resolved with antibiotics	-	-
Viable tissue	10%	90%	100%	-
Periwound	Maceration	Maceration	Maceration	Healthy
Exudate	Moderate, non-viscous, yellow/green	Moderate, non-viscous, clear/serous	Low, non-viscous, clear/serous	-
Pain score	2/10	2/10	2/10	0/10

Clinician perspective

"Treatment facilitated a reduction in the bioburden of the wound, with a concomitant decrease in wound exudate and an improvement in the condition of the periwound skin. A reduction in dressing change frequency decreased treatment costs and helped to improve the patient's well being and quality of life. The M.O.I.S.T. concept has provided me with a framework for planning and decision-making when treating my patient's wound in my daily clinical practice."

*Pain, warmth, erythema

CASE STUDY 5: DIABETES-RELATED FOOT ULCER WITH SEVERE INFECTION

Author: Chumpon Wilasrusmee, Professor of General Surgery, Faculty of Medicine, Ramathibodi Hospital, Mahidol University, Thailand

Patient and wound history

- 65-year-old female
- Medical history: Type 2 diabetes, peripheral arterial disease (ankle-brachial index = 0.7)
- Wound located on left medial foot; patient depressed and anxious about possible limb amputation; wound present for one month
- Surgical history: Surgical debridement of infected diabetes-related foot ulcer and left hallux amputation
- Previous treatment: Normal saline solution, povidone-iodine antiseptic solution and silver sulfadiazine.





Intervention and treatment regimen

- **Granudacyn® Wound Irrigation Solution** (intervention), a hypochlorous acid solution, was chosen to cleanse the wound and reduce risk of infection. **Granulox®** (intervention), a topical haemoglobin spray, was selected to improve wound bed oxygenation. **Exufiber® Ag+** (intervention), a gelling fibre dressing with silver, was chosen for its antimicrobial action and capacity to manage exudate
- Wound sites were surgically debrided and cleansed with Granudacyn® Wound Irrigation Solution
- The wound was coated with a thin layer of Granulox® spray and dressed with Exufiber® Ag+ (primary dressing) and gauze (secondary dressing). Offloading was provided in the form of crutches
- Dressings were changed every 2–5 days.

Table 6. Wound assessment and local treatment regimen following the principles of M.O.I.S.T.

Wound assessment		Local wound treatment
Moisture balance	Exudate was high, viscous and purulent	<ul style="list-style-type: none"> • Exufiber® Ag+ (silver-containing gelling fibre; primary dressing) • Gauze (secondary dressing)
Oxygen balance	<ul style="list-style-type: none"> • Peripheral arterial disease • Wound duration: >4 weeks • Slow healing response suggestive of hypoxia 	Granulox® (haemoglobin spray)
Infection control	Signs of severe infection (increased pain, warmth and exudate; erythema, oedema and malodour)	<ul style="list-style-type: none"> • Granudacyn® Wound Irrigation Solution (hypochlorous acid) • Exufiber® Ag+ (silver-containing gelling fibre dressing) • Antibiotics
Supporting strategies	Wound progression after treatment was initiated	Not required
Tissue management	90% of necrotic/sloughy tissue in wound bed	<ul style="list-style-type: none"> • Granudacyn® Wound Irrigation Solution (hypochlorous acid) for cleansing • Conservative, sharp debridement when necessary

Wound progression

	Initial study intervention (Day 1)	Day 12	Day 38	Day 129
				
Wound area	107cm ²	153cm ² (↑43%)	64cm ² (↓40%)	20cm ² (↓81%)
Wound depth	5cm	1cm (↓80%)	0cm (↓100%)	0cm
Signs of infection	Yes*	Improved	Resolved	-
Viable tissue	0%	25%	95%	100%
Peri wound	Unhealthy**	Improved	Healthy	Healthy
Exudate	High, viscous, purulent	Moderate, non-viscous, clear/serous	Low, non-viscous, clear/serous	Low, non-viscous, clear/serous
Pain score	9/10***	4/10	2/10	0/10

Clinician perspective

The use of Granudacyn®, Granulox® and Exufiber® Ag+ promoted the successful healing of an infected diabetes-related foot ulcer removing the need for limb amputation, whilst improving the patient's quality of life.

*Pain, warmth, increased exudate, erythema and oedema, **Severe erythema and maceration, ***Pain prior to dressing change and on dressing removal

CASE STUDY 6: PRESSURE ULCER

Author: Thi Pham Loan, Head Nurse, General Surgery, Nam Saigon International Hospital, Vietnam

Patient and wound history

- 59-year-old quadriplegic female
- Medical history: Type 2 diabetes, hypertension, heart disease, cerebrovascular disease, kidney disease, epilepsy, respiratory failure, symptoms of polyneuropathy, diarrhoea
- Wound located in the sacroiliac area; present for 15 days
- Surgical history: Laparoscopic anterior resection of mediastinal tumour (85 days prior); endotracheal intubation (65 days prior until Day 37); tube feeding (until Day 27)
- Previous treatment: Normal saline solution, povidone-iodine antiseptic solution and hydrocolloid dressing.

Intervention and treatment regimen

- **Granudacyn® Wound Irrigation Solution** (intervention), a hypochlorous acid solution, was chosen to cleanse the wound and facilitate mechanical debridement with moistened gauze. **Granulox®** (intervention), a topical haemoglobin spray, was selected to improve wound bed oxygenation. **Exufiber® Ag+** (intervention), a gelling fibre dressing with silver, was chosen for its antimicrobial action and capacity to manage exudate. **Mepilex® Ag** and **Mepilex® Border Sacrum** (interventions), silver and non-silver containing foam dressings, respectively, were selected for wound exudate management
- Mechanical debridement (gauze soaked in Granudacyn®) was performed at each dressing change from baseline until Day 27; the wound was cleansed with Granudacyn® throughout the study
- The wound was dressed with Exufiber® Ag+ (primary dressing), Mepilex® Ag and a water-resistant film (secondary dressings). From Day 19, a thin layer of Granulox® was applied to the wound and dressed with Mepilex® Border Sacrum. Granulox® treatment was discontinued on Day 37. Absorbable sutures were inserted on Day 45 to approximate the wound edges and aid epithelialisation. During the initial 27 days, the patient was turned in bed every 2–3 hours
- Median dressing change frequency was three days (range 2–15 days).




Table 7. Wound assessment and local treatment regimen following the principles of M.O.I.S.T.




Wound assessment		Local wound treatment
Moisture balance	Exudate was high, viscous and bloody	<ul style="list-style-type: none"> • Exufiber® Ag+ (silver-containing gelling fibre; primary dressing) • Mepilex® (non-bordered soft silicone foam; secondary dressing, secured with a film dressing) • After 3 weeks, regimen switched to Mepilex® Border Sacrum (self-adherent soft silicone foam dressing)
Oxygen balance	<ul style="list-style-type: none"> • Wound duration: >4 weeks • Slow healing response suggestive of hypoxia 	Granulox® (haemoglobin spray)
Infection control	Signs of infection (increased pain, warmth and exudate; erythema, oedema and malodour)	<ul style="list-style-type: none"> • Granudacyn® Wound Irrigation Solution (hypochlorous acid) • Exufiber® Ag+ (silver-containing gelling fibre dressing) • Antibiotics
Supporting strategies	Wound progression after treatment was initiated	Not required
Tissue management	85% necrotic/sloughy tissue in wound bed	<ul style="list-style-type: none"> • Granudacyn® Wound Irrigation Solution (hypochlorous acid) for cleansing • Conservative, sharp debridement when necessary

Clinician perspective

"The M.O.I.S.T. concept is an easy-to-use education tool and provides me with a common language from the hospital to the community. In addition, the use of Granudacyn® has a positive impact on reducing wound malodour and wound healing outcomes."

Wound progression

	Initial study intervention (Day 1)	Day 19	Day 27
			
Wound area	150cm ²	150cm ²	150cm ²
Wound depth	5cm	5cm	3cm (↓40%)
Signs of infection	Yes*	Improved with antibiotics	Improved
Viable tissue	0%	80%	100%
Periwound	Maceration	Healthy	Healthy
Exudate	High, viscous, serosanguinous/bloody	High, non-viscous, serosanguinous/bloody	Moderate, non-viscous, clear/serous
Pain score	6/10	4/10	2/10

	Day 37	Day 45	Day 60
			
Wound area	96cm ² (↓36%)	50cm ² (↓67%)	15cm ² (↓90%)
Wound depth	2cm (↓60%)	1cm (↓80%)	0.6cm (↓88%)
Signs of infection	Improved	None	None
Viable tissue	100%	100%	100%
Periwound	Healthy	Healthy	Healthy
Exudate	Low, non-viscous, clear/serous	None	None
Pain score	1/10	0/10	0/10

*Pain, warmth, increased exudate, mild erythema, oedema and malodour

CASE STUDY 7: FOOT ULCER

Author: Nguyen Duc Tuong, Nurse Practitioner, Endocrinology Department, People's Hospital 115, Vietnam

Patient and wound history

- 68-year-old female
- Medical history: Type 2 diabetes (insulin-required), hypertension, peripheral arterial disease
- Wound located on right foot; red, swollen, painful and infected; high body temperature; antibiotics prescribed
- Surgical history: Extensive surgical excision performed five days prior to study intervention.





Intervention and treatment regimen

- **Granudacyn® Wound Irrigation Solution** (intervention), a hypochlorous acid solution, was chosen to cleanse the wound and reduce risk of infection. **Granudacyn® Wound Gel** (intervention), a hypochlorous gel, was chosen to facilitate autolysis. **Mepilex®** (intervention), a conformable foam dressing, was selected for its effective management of exudate and prevention of maceration
- Wound debridement was performed using Granudacyn® Wound Gel on Day 1 (surgical debridement) and Day 4 (mechanical debridement). Granudacyn® Wound Irrigation Solution was used for wound cleansing during all dressing changes
- The wound was dressed with Mepilex® (primary dressing) and a fixation dressing
- Dressings were changed daily until Day 98, after which the frequency of dressing changes was reduced to every four days.

Table 8. Wound assessment and local treatment regimen following the principles of M.O.I.S.T.

Wound assessment		Local wound treatment
Moisture balance	Exudate was high, viscous and bloody	Mepilex® (non-bordered soft silicone foam dressing)
Oxygen balance	No issues suspected	Not required
Infection control	Acute infection with ascending cellulitis	<ul style="list-style-type: none"> • Granudacyn® Wound Irrigation Solution (hypochlorous acid) • Antibiotics
Supporting strategies	Wound progression after treatment was initiated	Not required
Tissue management	100% necrotic/sloughy tissue in wound bed with exposed underlying structures (tendon and ligaments) post-surgical debridement	<ul style="list-style-type: none"> • Granudacyn® Wound Irrigation Solution for cleansing • Granudacyn® Wound Gel (hypochlorous acid) for autolysis • Surgical debridement when necessary • NPWT for nine weeks post-surgical debridement

Wound progression

	Presurgical excision (Day -5)	Initial study intervention (Day 1)	Day 30	Day 107
				
Wound area: instep (A)		110cm ²	36cm ² (↓67%)	Both the instep wound and the wound on the sole had healed.
Wound depth: instep (A)		0.6cm	0cm (↓100%)	
Wound area: sole (B)		195cm ²	66cm ² (↓66%)	
Wound depth: sole (B)		2cm	1cm (↓50%)	
Signs of infection		Yes*	-	
Viable tissue		0%	90%	
Periwound		Unhealthy**	Healthy	
Exudate		High, viscous, purulent, sanguinous	Moderate, non-viscous, clear/serous	
Pain score		3/10***	0/10	

Clinician perspective

"The use of Granudacyn® Wound Irrigation Solution, Granudacyn® Wound Gel and Mepilex® promoted the successful healing of a severely infected diabetes-related foot ulcer. M.O.I.S.T. concept enabled informed clinical decisions to be made."

*Pain, increased exudate, erythema, oedema, moderate malodour, **Severe erythema and excoriation, ***Pain prior to dressing change, on dressing removal and during wound cleansing

CASE STUDY 8: LEG ULCER

Author: Thanate Thanasarnwimon, Plastic Surgeon, Burapha University Hospital, Thailand

Patient and wound history

- 70-year-old male
- Medical history: Type 2 diabetes, hypertension, peripheral arterial disease, heart disease, kidney disease, poor nutritional status
- Original third degree burn (from self-prescribed hot compression) transitioned to chronic ulcer exposed to the bone; present for 15 months
- Surgical history: Debridement and drill holes on tibia (188 days prior); debridement and matrix wound dressing placement (72 days prior); aorto bifemoral bypass (19 days prior); debridement and partial de-cortical tibia and ankle bone (seven days prior); percutaneous balloon angioplasty right superficial femoral artery; right popliteal artery (Day 21)
- Previous treatment: Wet-to-dry gauze dressing (daily changes).




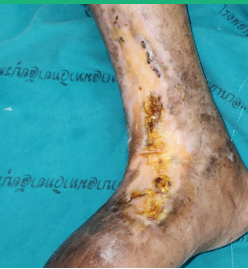
Intervention and treatment regimen

- **Granudacyn® Wound Irrigation Solution** (intervention), a hypochlorous acid solution, was chosen to cleanse the wound and reduce risk of infection. **Granulox®** (intervention), a topical haemoglobin spray, was selected for its ability to improve wound bed oxygenation to support healing. **Mepilex® Ag** (intervention), a conformable foam dressing with silver, was chosen for its antimicrobial action, effective exudate management and prevention of maceration
- At Day 21, the wound was debrided (sharp with curette). Granudacyn® was used to cleanse the wound during all dressing changes
- Over the initial 21 days, the wound was coated with a thin layer of Granulox® and dressed with Mepilex® Ag (primary dressing)
- Over the following 19 days, chlorhexidine gauze and NPWT were used; however, due to increased pain, treatment reverted to Granulox® and Mepilex® Ag; an elastic bandage provided retention
- Granulox®/Mepilex® Ag dressings were changed every 2-5 days.

Table 9. Wound assessment and local treatment regimen following the principles of M.O.I.S.T.

Wound assessment		Local wound treatment
Moisture balance	Exudate was moderate, non-viscous and clear/serous	Mepilex® Ag (silver-containing foam dressing)
Oxygen balance	<ul style="list-style-type: none"> ▪ Peripheral arterial disease ▪ Wound duration: >5 weeks ▪ Slow healing response suggestive of hypoxia 	Granulox® (haemoglobin spray)
Infection control	Suspected presence of biofilm	<ul style="list-style-type: none"> ▪ Mepilex® Ag (silver-containing foam dressing) ▪ Antibiotics
Supporting strategies	Wound progression after treatment was initiated	Not required
Tissue management	90% slough tissue in wound bed with exposed bone	<ul style="list-style-type: none"> ▪ Granudacyn® Wound Irrigation Solution (hypochlorous acid) for cleansing ▪ Surgical debridement ▪ NPWT for three weeks post-surgical debridement

Wound progression

	Initial study intervention (Day 1)	Day 40	Day 103	Day 162
				
Wound area	30cm ²	12cm ² (↓60%)	0.5cm ² (↓98%)	Healed
Signs of infection	Yes*	None	None	-
Viable tissue	0%	25%	95%	-
Periwound	Unhealthy**	Healthy	Healthy	Healthy
Exudate	Moderate, non-viscous, clear/serous	Low, non-viscous, clear/serous	Low, non-viscous, clear/serous	-
Pain score	5/10***	1/10	0/10	-

Clinician perspective

"The use of Granudacyn®, Granulox® and Mepilex® Ag promoted the successful healing of a chronic, infected leg ulcer, removing the need for limb amputation."

*Severe increased exudate and erythema, moderate malodour; antibiotics prescribed, **Mild erythema; ***Pain prior to dressing change, on dressing removal, during wound cleansing and on dressing reapplication

CASE STUDY 9: FOOT ULCER

Author: Nguyen Thi Thu Ha, Head of Intensive Care Unit and Vu Thi Kim Tuyet, Nong Nghiep General Hospital, Vietnam

Patient and wound history

- 57-year-old male
- Medical history: Type 2 diabetes, hypertension, chronic kidney disease, cirrhosis, ventilator-associated pneumonia, parenteral nutrition
- Severely infected wound located on right dorsal foot; present for approximately 27 days
- Previous treatment: Povidone-iodine, cotton gauze, antibiotics.





Intervention and treatment regimen

- **Granudacyn® Wound Irrigation Solution** (intervention), a hypochlorous acid solution, was chosen to cleanse the wound and reduce risk of infection. **Granulox®** (intervention), a topical haemoglobin spray, was selected for its ability to improve wound bed oxygenation to support healing. **Exufiber® Ag+** (intervention), a silver-containing gelling fibre dressing, was chosen for its antimicrobial action along with its capacity to manage exudate. **Mepilex® Ag** (intervention), a silver-containing foam dressing with a soft silicone (Safetac®) wound contact layer, was selected for exudate management
- Wound site was debrided (sharp) and cleansed with Granudacyn® Wound Irrigation Solution
- Wound was coated with a thin layer of Granulox® spray, and dressed with Exufiber® Ag+ (primary dressing) and Mepilex® Ag (secondary dressing)
- Initially, dressings were changed daily; from Day 4 onwards, dressings were changed every 2-3 days.

Table 10. Wound assessment and local treatment regimen following the principles of M.O.I.S.T.

Wound assessment		Local wound treatment
Moisture balance	Exudate was high, viscous and purulent	<ul style="list-style-type: none"> • Exufiber® Ag+ (silver-containing gelling fibre; primary dressing) • Mepilex® Ag (silver-containing, non-bordered soft silicone foam; secondary dressing)
Oxygen balance	<ul style="list-style-type: none"> • Wound duration: >4 weeks • Slow healing response suggestive of hypoxia 	Granulox® (haemoglobin spray)
Infection control	Signs of infection (increased pain, warmth, exudate and malodour)	<ul style="list-style-type: none"> • Granudacyn® Wound Irrigation Solution (silver-containing gelling fibre; primary dressing) • Mepilex® Ag (silver-containing, non-bordered soft silicone foam; secondary dressing) • Antibiotics
Supporting strategies	Wound progression after treatment was initiated	Not required
Tissue management	100% necrotic/sloughy tissue in wound bed with exposed tendons	<ul style="list-style-type: none"> • Granudacyn® Wound Irrigation Solution (hypochlorous acid) for soaking (pre-debridement) • Conservative, sharp debridement when necessary

Wound progression

	Initial study intervention (Day 1)	Day 4	Day 18	Day 20
Wound area	 102cm ²	 102cm ²	 90cm ² (↓12%)	 83cm ² (↓19%)
Signs of infection	Yes*	Improved	Improved	Resolved
Viable tissue	0%	50%	100%	100%
Periwound	Severe maceration	Healthy	Healthy	Healthy
Exudate	High, viscous, purulent	High, viscous, purulent/serosanguinous	Moderate, non-viscous, clear/serous	Low, non-viscous, clear/serous
Pain score	9/10**	7/10**	7/10**	5/10**

Clinician perspective

"The M.O.I.S.T. concept has given us a structured framework for treating complex wounds. The treatment solutions - Granudacyn®, Granulox®, and Safetac®-based dressings (Mepilex® Ag) are very effective for tendon-risk conditions."

*Severe increased pain, warmth, exudate and malodour, **Pain prior to dressing change, on dressing removal, during cleansing and on dressing reapplication

CASE STUDY 10: PRESSURE ULCER

Author: Ha Van Tuan, Orthopaedic Consultant, Orthopaedic Department, Thanh Nhan Hospital, Vietnam

Patient and wound history

- 85-year-old female
- Medical history: Type 2 diabetes, hypertension, heart disease, kidney disease; admitted to intensive care unit with COVID-19
- Wound located on sacrum; present for 40 days
- Previous treatment: Surgical debridement, povidone-iodine antiseptic solution and cotton gauze.



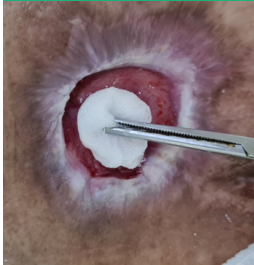
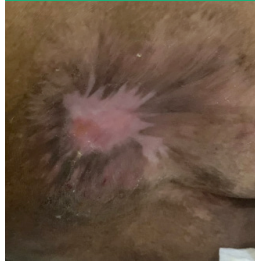
Intervention and treatment regimen

- **Granudacyn® Wound Irrigation Solution** (intervention), a hypochlorous acid solution, was chosen to cleanse the wound and reduce risk of infection. **Granulox®** (intervention), a topical haemoglobin spray, was selected for its ability to improve wound bed oxygenation to support healing. **Exufiber®** (intervention), a gelling fibre dressing, was chosen for its capacity to manage exudate and promote autolytic debridement to support a clean wound bed upon dressing removal. **Mepilex®** (intervention), a conformable foam dressing, was selected for its effective management of exudate and prevention of maceration
- Periodic sharp wound debridement was performed until Day 20 while the patient was an in-patient. Granudacyn® was used to cleanse the wound during all dressing changes
- The wound was coated with a thin layer of Granulox®, and Exufiber® was applied as the primary dressing, with Mepilex® as the secondary dressing. An air mattress was used for offloading
- Initially, dressings were changed daily; from Day 8 onwards, dressing change was every two days.

Table 11. Wound assessment and local treatment regimen following the principles of M.O.I.S.T.

Wound assessment		Local wound treatment
Moisture balance	Exudate was high, non-viscous and bloody	<ul style="list-style-type: none"> • Exufiber® Ag+ (silver-containing gelling fibre; primary dressing) • Mepilex® (non-bordered soft silicone foam; secondary dressing)
Oxygen balance	No issues suspected	Not required
Infection control	Signs of infection (increased pain, warmth, exudate, and malodour)	<ul style="list-style-type: none"> • Granudacyn® Wound Irrigation Solution (hypochlorous acid) • Exufiber® Ag+ (silver-containing gelling fibre dressing) • Antibiotics
Supporting strategies	Wound progression after treatment was initiated	Not required
Tissue management	>80% necrotic/sloughy tissue in wound bed	<ul style="list-style-type: none"> • Granudacyn® Wound Irrigation Solution for cleansing • Sharp debridement when necessary

Wound progression

	Initial study intervention (Day 1)	Day 9	Day 92	Day 152
				
Wound area	182cm ²	90cm ² (↓51%)	7.5cm ² (↓96%)	Healed
Wound depth	3.5cm	2.8cm (↓20%)	0.7cm (↓80%)	Healed
Signs of infection	Yes* (antibiotics)	Improved (antibiotics)	Resolved	-
Viable tissue	20%	90%	95%	-
Periwound	Unhealthy**	Healthy	Healthy	Healthy
Exudate	High, non-viscous, brown/bloody	High, non-viscous, clear/serous	Moderate, non-viscous, clear/serous	-
Pain score	8/10***	6/10***	4/10***	-

Clinician perspective

"The M.O.I.S.T. concept provides straightforward and simplified guidance, coupled with Mölnlycke intuitive solutions. The use of Granudacyn®, Granulox®, Exufiber® and Mepilex® promoted the successful healing of an infected stage 4 pressure ulcer."

*Severe increased pain, exudate, erythema, malodour and moderate warmth, **Moderate maceration, ***Pain prior to dressing change, on dressing removal, during cleansing and on dressing reapplication

CASE STUDY 11: ILIAC AND SACRAL PRESSURE INJURIES/ULCERS

Author: Nabilah Aziz, Medical Officer, Global Doctors Hospital, Mont Kiara, Malaysia

Patient and wound history

- 83-year-old male
- Medical history: Iron-deficient anaemia, osteoarthritis (right hip), benign prostatic hyperplasia, dyslipidemia, dementia; bed-bound for three months
- Pressure ulcers located on (A) posterior superior iliac spine (B) sacrum; present for one month
- Surgical history: Left femoral neck fracture (nail fixation)
- Communication issues due to hearing loss and language barrier
- Previous treatment: Homecare with gauze and tape; no offloading or turning.

Intervention and treatment regimen

- **Granudacyn® Wound Irrigation Solution** (intervention), a hypochlorous acid solution, was chosen to cleanse the wound and facilitate debridement with moistened gauze. **Granulox®** (intervention), a topical haemoglobin spray, was selected to improve wound bed oxygenation. **Mepilex® Border Flex** and **Mepilex® Border Sacrum** (intervention), foam dressings, were chosen for exudate management. **Exufiber® Ag+** (intervention), a silver-containing gelling fibre dressing, was selected to pack undermining and manage exudate
- During the initial seven days of study, the patient was treated at home (caregiver and family). On Day 8, the patient was hospitalised due to pneumonia and anaemia. Inpatient wound management commenced thereafter, with antibiotics prescribed for pneumonia
- Wound debridement was performed from Day 1-19 (sharp) and from Day 55 onwards (mechanical, either with gauze soaked in Granudacyn® or a debridement tool). Wounds were cleansed with normal saline from Days 1-25, with Granudacyn® used thereafter
- Wound A was dressed with Mepilex® Border Flex and Wound B with Mepilex® Border Sacrum, both secured using retention tape. From Day 52, the wounds were coated twice weekly with a thin layer of Granulox® before dressing application; frequency increased to three times weekly on Day 71. At Day 46, Exufiber® Ag+ was introduced to lightly pack undermining. On Day 66, a transparent tape was used for dressing retention, leading to a medical adhesive-related skin injury and skin tear; hydrocolloid dressing was applied to the periwound area for eight days until this had resolved. A ripple mattress was used throughout the study
- Dressings were changed every other day until Day 71, after which dressing change frequency was every 2-4 days.

Table 12. Wound assessment and local treatment regimen following the principles of M.O.I.S.T.




Wound assessment		Local wound treatment
Moisture balance	Exudate was moderate, non-viscous and green/yellow	<ul style="list-style-type: none"> • Mepilex® Border Flex (for iliac pressure ulcer) • Mepilex® Border Sacrum (for sacral pressure ulcer; self-adherent, soft silicone foam dressings) • Exufiber® Ag+ (silver-containing gelling fibre dressing; primary dressing) at a later timepoint to lightly pack the undermining area
Oxygen balance	<ul style="list-style-type: none"> • Wound duration: >4 weeks • Slow healing response suggestive of hypoxia 	Granulox® (haemoglobin spray)
Infection control	<ul style="list-style-type: none"> • Sign of infection (malodour) • Undermining area at high risk of contamination 	<ul style="list-style-type: none"> • Granudacyn® Wound Irrigation Solution (hypochlorous acid) • Exufiber® Ag+ (silver-containing gelling fibre dressing)
Supporting strategies	Wound progression after treatment was initiated	Not required
Tissue management	>90% necrotic/sloughy tissue in wound bed	<ul style="list-style-type: none"> • Granudacyn® Wound Irrigation Solution (hypochlorous acid) for cleansing • Conservative, sharp debridement when necessary

Clinician perspective

"After 14 weeks of treatment, the condition of both pressure ulcers had improved. Both wounds were significantly reduced in size. Wound A (iliac pressure ulcer) decreased in size by 84% to 4cm², while wound B (sacral pressure ulcer) decreased in size from 60% to 35cm². Wound undermining was resolved in wound A and reduced in wound B. Both wounds exhibited wound contracture with advancing epithelial edges and increased wound bed tissue viability. Removal of Mepilex® Border dressing was pain-free, and the periwound skin was protected from maceration and skin tears."

Wound progression

	Initial study intervention (Day 1)	Day 25	Day 53
			
Wound area (A/B)	24.8cm ² /88cm ²	20cm ² (↓19%)/76cm ² (↓14%)	14cm ² (↓44%)/68cm ² (↓23%)
Undermining (A)	3cm at 12 o'clock position	1.5cm at 12 o'clock position (↓50%)	1.5cm at 12 o'clock position
Undermining (B)	5cm from 4-5 o'clock position and 4cm from 9-12 o'clock position	3.5cm from 9-12 o'clock position (↓13%)	2cm from 9-12 o'clock position (↓50%)
Signs of infection	Mild malodour	None	None
Viable tissue	90%	70%	90%
Periwound	Mild erythema	Healthy	Healthy
Exudate	Moderate, non-viscous, yellow/green	High, non-viscous, clear/serous	High, non-viscous, clear/serous
Pain score	5/10*	0/10	0/10

	Day 67	Day 90	Day 98
			
Wound area (A/B)	9cm ² (↓64%)/60cm ² (↓32%)	6.2cm ² (↓75%)/35cm ² (↓60%)	4cm ² (↓84%)/35cm ²
Undermining (A)	1.5cm at 9 o'clock position	0cm	0cm
Undermining (B)	1.5cm from 9-12 o'clock position (↓63%)	1cm from 9-12 o'clock position (↓75%)	1cm from 9-12 o'clock position
Signs of infection	None	None	None
Viable tissue	90%	90%	90%
Periwound	Deteriorated (medical adhesive-related skin injury; skin tear)	Healthy	Healthy
Exudate	High, non-viscous, clear/serous	High, non-viscous, clear/serous	High, non-viscous, clear/serous
Pain score	0/10	0/10	0/10

*Pain only during dressing removal

WOUNDS | INTERNATIONAL

www.woundsinternational.com